

---

**(*Aeromonas hydrophila*)**  
**(*Oncorhynchus mykiss*)**

\*

دانشیار گروه شیلات و محیط زیست، دانشکده منابع طبیعی دانشگاه تهران، ایران  
استادیار گروه شیلات دانشکده منابع طبیعی و محیط زیست دانشگاه صنعتی خاتم الانبیا بهبهان، ایران

(    //    :                      //    :                      )

(*Oncorhynchus mykiss*)

( $p < /$  )

...

(Morrison and Bucklin, 1996)

*A. hydrophila*

(Majumdar *et al.*, 2006)

Akhlaghi )

(and Vafae, 2002

Li *et al.*, )

(2006

(Tvakoli and Akhlaghi, 2009 )

*Oncorhynchus* )

(*mykiss*

*A. media* *A. salmonicida*

(Mahon and Manuselis, 2000)

*O. mykiss*

Soltandalal )

*et al.*, 2005; Doubaradran *et al.*, 2006; Halakou *et al.*, 2008  
*Aeromonas* spp.

± °C )

( L/ D / ± / mg/l

(LPS)

LPS (Chopra and Houston, 1999)

---

%

%

(PBS: 7.2)                      CC

/      /

/ ×                      (RTCC) *A. hydrophila*

(TSA)

( pH 7.)

× (cfu ml<sup>-1</sup>)                      PBS                      (Joseph and Carnahan, 1994)

(TSB)

***A. hydrophila***                      pH: / (PBS)

%                      LD<sub>50</sub>

cfu ml<sup>-1</sup>

)

(

(TSA)                      ( )

LD<sub>50</sub>

cfu ml<sup>-1</sup>

*A. hydrophila*                      *A. hydrophila*

× cfu ml<sup>-1</sup>

/      %                      % /

(Joseph and Carnahan, 1994)

(WBC)                      (RBC)

...

Kolmogorov-

(Hct)

Smirrov Normality Test

Arcsin

%

-

( $p < /$  )

( $p < /$  )

< / )

( $p < /$  )

( $p$

*A. hydrophila*

( )

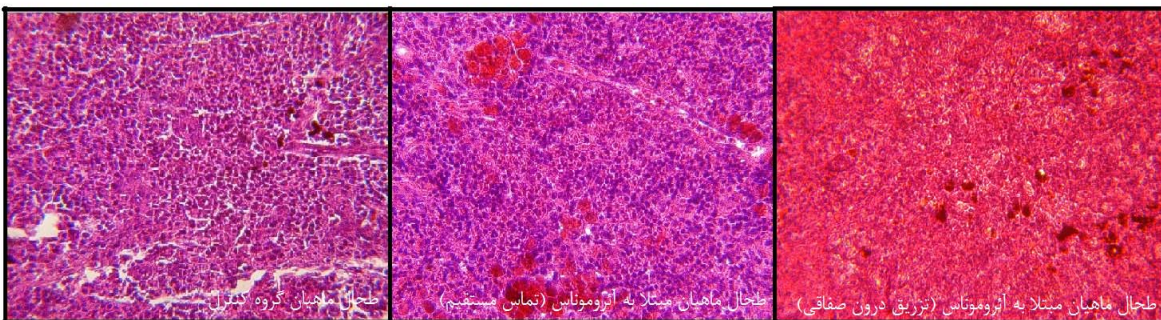
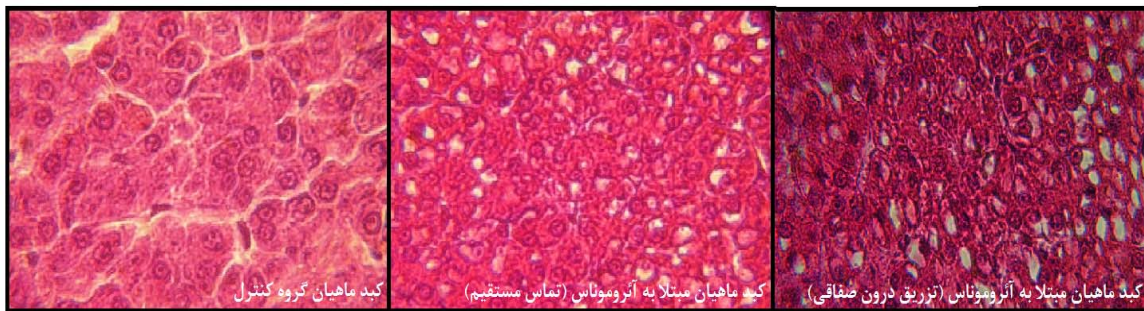
Mintab (13)

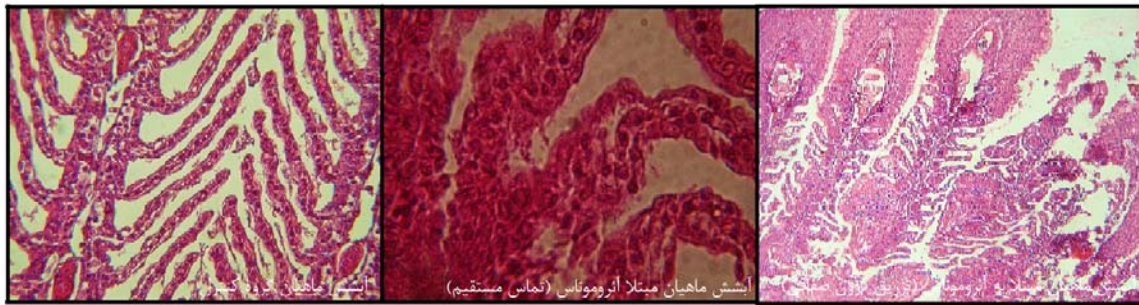
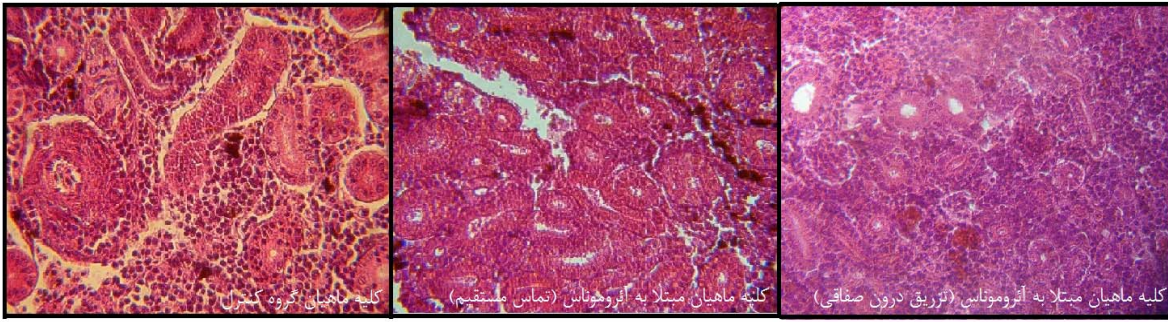
(ANOVA)

	/ ± / b	/ ± / a	/ ± / a
	± / b	/ ± / a	/ ± / a
	/ ± / a	/ ± / b	/ ± / b
	/ ± / b	± / a	/ ± / ab
	/ ± / b	/ ± / ab	/ ± / a
	± / a	/ ± / b	± / b

%

	+	
	+	
	- + +	SIM
	-	
	+	
	-	VP
	-	
	-	
	-	
	-	





(Pemberton *et al.*, 1997

(Chopra *et al.*, 1993)

*A. hydrophila*

(Howard and Buckley, 1985)

Akhlaghi and Vafaei, )

(2002)

(Akhlaghi, 2000)

Merino *et al.*, 1995; )

- 
- <sup>5</sup> Gelatinase
  - <sup>6</sup> Chitinase
  - <sup>7</sup> Cytotoxic enterotoxins
  - <sup>8</sup> Aerolysin
  - <sup>9</sup>  $\beta$ -hemolysin
  - <sup>10</sup>  $\alpha$ -hemolysin

- 
- <sup>1</sup> Proteases
  - <sup>2</sup> Elastase
  - <sup>3</sup> Lecithinase
  - <sup>4</sup> Amylase

---

(WBC)

( $p < /$  )

*O. niliticus*

Ahmed and )

(Tvakoli and Akhlaghi, 2009)

(Shoreit, 2001; Gamal *et al.*, 2002

( $p < /$  )

(Hct)

(RBC)

NADPH

Dalmo )

(*et al.*, 1997

(Johnston, 1978)

*A. hydrophila*

(Howard *et al.*, 1987; Parker *et al.*, 1994)

*A. hydrophila*

9

*A. hydrophila*

(Tvakoli and Akhlaghi, 2009)

( $p < /$  )

...

---

( )

(Alishahi *et al.*, 2009)

Ahned and Shoreit, 2001; Gamal *et al.*, )  
(2002

Merino *et al.*, 1995; Pemberton *et al.*, )  
Chopra *et* ) (1997  
(*al.*, 1993

(Howard and Buckley, 1985)

(Abu-El-Saad, 2007)

---

<sup>1</sup> Vergani *et al.* (1999)



---

## References

- Abu-El-Saad, A.S. 2007. Immunomodulating effect of inositol hexaphosphate against *Aeromonas hydrophila*-endotoxin. *Immunobiology* 212: 179-192.
- Ahmed, S.M. and A.A.M. Shoreit, 2001. "Bacterial hemorrhagic septicemia in *Oreochromis niloticus* at Aswan fish hatcheries". *Assiut Vet. Med. J.* Vol. 45, No. 89, April 2001.
- Akhlaghi, M. 2000. Immunogenicity of *Aeromonas hydrophila* in Common Carp (*Cyprinus carpio*. L). *Journal of Veterinary Research*. 55(1): 57-62.
- Akhlaghi, M. and A. Vafaei, 2002. Pathogenicity of *Aeromonas hydrophila* in Aquarium Fish. *Iranian Journal of Veterinary Research*. 3(1): 82-87.
- Akhlaghi, M. and H. Tavakoli, 2009. Study of Lysozyme, Immunoglobulin, Blood Cell and Hematocrit Changes Following Experimental Infection with a Pathogenic *Aeromonas hydrophila* in Rainbow Trout. *Journal of Veterinary Research*. 64(2): 157-162.
- Alishahi, M. M. Soltani, and A. Zargar, 2009. Bacteriological Study of Grass Carp (*Ctenopharyngodon idella*) Mortality in Khuzestan Province. *Scientific Research Iranian Veterinary Journal*. 4(5(22)): 25-34.
- Chopra, A.K. C.W. Peterson, and G.F. Jin, 1993. Cloning, expression and sequence analysis of cytolytic enterotoxin gene in *Aeromonas hydrophila*. *Canadian Journal of Microbiology*, 39: 513-523
- Chopra, A.K. and C.W. Houston, 1999. Enterotoxins in *Aeromonas* associated gastroenteritis.. *Microbes and Infection*, 1: 1129-1137.
- Dalmo, R.A. K. Ingebrightsen, and J. Bogwald, 1997. Non-specific defense mechanisms in fish, with particular reference to the reticuloendothelial system (RES). *Journal of Fish Diseases*, 20: 241-273,
- Dobaradaran, S. B. Bina, and B. Nasrisfahani, 2006. The Effect of Some Physical and chemical Parameters on Regrowth of *Aeromonas* Bacterium and Heterotrophic Bacteria in Isfahan Drinking water System. *Water and Wastewater*; 17 (57): 8-13.
- Fang, J.S. J.B. Chen, and W.J. Chen, 1999. Hemolytic uremia syndrome in an adult male with *Aeromonas hydrophila* enterocolitis. *Journal of Nephrology Dialysis Transplantation*, 14: 439-440.
- Halakou, A. N.A. Mozafar, and H. Forohesh, 2008. The Distribution of *Aeromonas* SPP. From the Surface waters of Golestan Province in Iran. *Journal of Sciences (Islamic Azad University)*, 17(66): 25-29.
- Howard, S.P. and J.T. Buckley, 1985. Activation of the hole forming toxin aerolysin by extracellular processing. *Journal of Bacteriology*, 163:336-340
- Howard, S.P. W.J. Garland, J.M. Green, and J.T. Buckley, 1987. Nucleotide sequences of the gene for the hole-forming toxin aerolysin of *Aeromonas hydrophila*. *Journal of Bacteriology* 169: 2869-2871
- Johnston, R.B. 1980. Jr Oxygen metabolism and the microbicidal activity of macrophages. *Fed Proc* 37: 2759-2764, 1978
- Joseph, S.W. and A. Carnahan, 1994. The Isolation, identification, and systematic of the motile *Aeromonas* species. *Annual Review of Fish Diseases*, 4: 315-43.
- Koneman, E. S. Allen, W. Janda, W. Winn, G. Procop, P. Schreekenberger, and G. Wood, 2006. *Atlas and Textbook of Diagnostic Microbiology*. 6th ed. Lippincott, Philadelphia, 417
- Mahon, C.R. and G. Manuselis, 2000. *Textbook of Diagnostic Microbiology*. W.B. Sanders Co, Philadelphia, 524
- Majumdar, T. S. Ghosh, J. Pal, and S. Mazumder, 2006. Possible role of a plasmid in the pathogenesis of a fish disease caused by *Aeromonas hydrophila*. *Aquaculture*, 256 (1-4): 95-104.
- Merino, S. X. Rubires, S. Knochel, and J.M. Tomas, 1995. Emerging pathogens: *Aeromonas* spp. *International Journal of Food Microbiology* 28:157-168
- Mohamed, G.A. M.M.S. Fouda, and H.S. Hussein, 2002. *Aeromonas hydrophila* infection in male monosex *O. niloticus* fish reared in floating cages. 6th Vet. Med. Zag. Conference (7-9 Sept. 2002), Hurgada, Egypt.
- Morrison, D.C. and S.E. Bucklin, 1996. Evidence for antibiotic mediated endotoxin release as a contributing factor to lethality in experimental gram-negative sepsis. *Scand. J. Infect. Dis. Suppl.* 101: 3-8.
- Parker, M.W. J.T. Buckley, J.P.M. Postma, A.D. Tucker, K. Leonard, F. Pattus, and D. Tsernoglou, 1994. Structure of the *Aeromonas* toxin proaerolysin in its water-soluble and membrane- channel states. *Nature* 367:292-295

...

- 
- Pemberton, J.M. S.P. Kidd, and R. Schmidt, 1997. Secreted enzymes of *Aeromonas*. FEMS Microbiology Letters 152: 1–10
  - Soltandalal, M.M. Z. Ghalavand, and B. Nikmanesh, 2005. Investigation of Infection Rate to Intestinal Pathogens and *Aeromonas* Species in Children Suffering from Gastroenteritis at Tehran Children's Medical Center, 2004-2005. Journal of Zanjan University of Sciences and Health services; 13(52): 37-42.
  - Vergani, G. M.T. Portoles, and R. Pagani, 1999. Escherichia coli lipopolysaccharide effects on proliferating rat liver cells in culture: a morphological and functional study. Tissue Cell 31, 1–7.
  - Xiao-liang, L. S. Jiang-bing, and F. Wei-huan, 2006. Protection of *Carassius auratus Gibelio* against infection by *Aeromonas hydrophila* using specific immunoglobulins from hen egg yolk. J Zhejiang University Science B, 7(11): 922-928.

## Histopathology and Hematology in rainbow trout (*Oncorhynchus mykiss*) following experimental infection with *Aeromonas hydrophila*

K. Ahmadi<sup>1</sup>, A.R. Mirvaghefi<sup>\*2</sup>, M. Banaee<sup>3</sup> and M. Mousavi<sup>4</sup>

<sup>1</sup>Master Science of Fisheries, young researchers club, Tehran North Branch, Islamic Azad University, Tehran, I.R. Iran

<sup>2</sup>Associate professor in University of Tehran, I.R. Iran

<sup>3</sup>Assistant professor, Behbahan University of Technology, Environment and Natural Resource College, I.R. Iran

<sup>4</sup>M. Mousavi- University of Tehran, I.R. Iran

(Received: 04/07/2010 , Accepted: 14/08/2011)

### Abstract

To investigate the hispathological characteristics in liver, kidney, spleen and gills of rainbow trout, *Oncorhynchus mykiss* following experimental infection with *Aeromonas hydrophila*, septicemia agents in fish were infected through injected intraperitoneally and direct contact with  $10^7$  bacteria per liter solution. Mortality and clinical diagnostic were recorded in experimental periods. After 14 days, blood and tissues were sampled of survival fish. A significant decreased in RBC, Hb, lymphocytes and monocyte ( $p < 0.05$ ) and significant increase in WBC and neutrophile ( $p < 0.05$ ) is the most important changes in hematological index of infected fish by *A. hydrophila*. Presence of bacteria in the tissues were confirmed the by biochemical tests. Tissues were normal in the control group. The apparent disorganization of live cells, cytoplasmic and nuclear material deposition, the rupture of blood sinuses, hypertrophy of hepatocytes, degeneration, hemorrhage, vacuolization of cell cytoplasm in liver tissue; a significant deposition of hemosiderin granules in a melanomacrophage center and morphological alterations in ellipsoid cells in spleen tissue; degeneration and necrosis of renal tubules, glomerular lesions, shrinking of the glomerulus and enlargement of space inside Bowman's capsule, dwindling of the tubular lumen in kidney tissue; hyperplasia, necrosis of epithelial filament, shortening of secondary lamellae and lamellar fusion in gills are important histopathological damage observed in tissues of infected fish with *A. hydrophila*.

**Keywords:** *Aeromonas hydrophila*, Histopathology, Hematological index, Rainbow trout

