

Preventive effect of omega-3 fatty acids on ethinyl estradiol-induced hepatosteatosis in female wistar rat

Chahardah Cherick, M.¹, Shahriari, A.^{1*}, Asadian, P.², Esmailzadeh, S.³

¹Department of Basic Sciences, Faculty of Veterinary Medicine Shahid Chamran University, Ahwaz, Iran

²Department of Clinical Sciences, Faculty of Veterinary Medicine, Lorestan University, Khoramabad, Iran

³Department of Pathobiology, Faculty of Veterinary Medicine, Shahid Chamran University, Ahwaz, Iran

Key words:

hepatosteatosis, rat, ethinylestradiol, AST, ALT

Correspondence

Shahriari, A.
Department of Biochemistry, Faculty of Veterinary Medicine, Shahid Chamran University, Ahwaz, Iran
Tel: +98(611) 3330073
Fax: +98(611) 3360807
Email: a.shahriari@scu.ac.ir

Received: 6 February 2013

Accepted: 15 April 2013

Abstract:

BACKGROUND: Hepatic steatosis due to estrogen therapy increases the activity of inflammatory markers, particularly the activity of TNF α which in turn induces more lipogenesis. Omega-3 fatty acids are among the negative regulators of hepatic lipogenesis. **OBJECTIVES:** In this research, the preventive effect of omega-3 fatty acids on estrogen-induced steatosis in rats was evaluated. **METHODS:** 2 mg/kg. BW/SC of 17 α -ethinyl-lestradiol were injected into 25 female wistar rats in 5 equal groups (excluding the control group) over 10 consecutive days. Simultaneously, 3 of estradiol-treated groups were orally given 250, 500, and 1000 mg/kg. BW omega-3 fatty acids, respectively. At the end of the experiment, plasma ALT, AST, and TNF α level were determined. Histopathological changes in the liver were also identified by the evaluation of samples stained with H&E and Oil Red O. **RESULTS:** The histological findings revealed hepatic microvesicular steatosis and fat deposit in ethinylestradiol and, to a lesser extent, in the 250 mg/kg BW omega-3 fatty acids groups. The plasma levels of AST, ALT, and TNF α significantly increased in the ethinylestradiol group compared to the control ($p < 0.05$) and 1000 mg/kg. B.W omega-3 group. Omega-3 fatty acids reduced these parameters in comparison to the estradiol group ($p < 0.05$). **CONCLUSIONS:** It was concluded that 1000mg/kg.BW of omega-3 protects the liver against steatotic injuries.

Introduction

Nonalcoholic fatty liver disease (NAFLD) is rapidly growing as a world-wide public health problem. NAFLD involves a wide range of disorders, from simple steatosis through steatohepatitis, fibrosis and cirrhosis to hepatocarcinoma (Adam et al., 2006; Clark et al., 2002). Hepatic steatosis is characterized by the macro and microvesicular fat droplets in hepatocytes (Dasi et al., 2003). This abnormality is associated with metabolic disorders such as obesity and diabetes and is closely linked to insulin resistance (Haque et al., 2002; Jesus et al.,

2004). However, the pathogenesis of steatosis is complex and incompletely understood, but available evidence have demonstrated that excessive free fatty acids (FFA) in the liver which are esterified to triglyceride (TG) make initial lesions (first hit) that predispose the liver to aggressive effect of oxidative stress, mitochondrial abnormalities, hormonal disturbance involving leptin and adiponectin and proinflammatory cytokines (second hit) induce steatohepatitis, fibrosis and cirrhosis (Carl et al., 2002; Day et al., 1998). Among these factors, pro-inflammatory cytokines, specifically TNF seems to be a prominent factor for pathogenesis of the hepatic

steatosis (Endo et al., 2007). Accumulated TG in hepatocytes is metabolized via mitochondrial or peroxisomal oxidation, which, in turn, increases reactive oxygen species (ROS). ROS cause lipid peroxidation followed by the activation of an inflammatory response and hepatic stellate cells, leading to fibrosis (Day et al., 1998; Endo et al., 2007; Erdogan et al., 2004). Estrogen derivatives are well known to cause intrahepatic cholestasis in susceptible women during pregnancy and also followed by administration of oral contraceptive and postmenopausal replacement therapy (Bouchard et al., 1993). As well, some evidence have demonstrated that estrogen is lipogenic for liver (Abraham et al., 1980). These two properties may predispose the liver to hepatosteatosis. Omega-3 fatty acids (O3Fas) from fish oil, eicosapentaenoic acid (EPA) and docosapentaenoic acid (DHA), have many biological functions (El-badry et al., 2007). These fatty acids have hypolipidemic, anti-inflammatory and antioxidant effects (Carl et al., 2002). It has also been shown that these acids provide improvements to NAFLD patients (El-Badry et al., 2007; Erdogan et al., 2004; Hao et al., 2010). In addition, omega-3 fatty acids have been reported to decrease de novo lipogenesis via down-regulation of the sterol regulatory element binding protein-1 (SREBP-1) and induce fatty acids catabolism through the activation of the Peroxisome proliferator-activated receptor (PPAR- α) mediated pathway in the liver (El-badry et al., 2007; Hao et al., 2010). They may have antioxidant effects by inhibiting lipid peroxidation. In an animal study, omega-3 fatty acids supplementation decelerated progression of oxidative stress and influenced pathways involved in oxidation and inflammation (Iraz et al., 2005; Kajikawa et al., 2003). In accordance to the above mentioned information, this study was conducted to evaluate the preventive effect of omega-3 fatty acids on estradiol-induced hepatosteatosis in female rats.

Materials and Methods

The OmegaFlex softgels were acquired from International Agencies (Davie, FL 33317, USA) and 17 α -ethinylestradiol was obtained from Aburairhan pharmaceutical Co. (Tehranpars, Tehran, Iran). The

ALT/AST kit was purchased from Ziestchem (Tehran, Iran). The TNF- kit was provided by Bender med system (1030 Vienna, Austria) and all the chemicals used in Oil Red O and H&E staining were obtained from Merck (Germany). 25 female wistar rats (6 weeks of age) were purchased from the laboratory animal breeding council (Ahvaz Jondishapoor University of Medical Science, Iran). They were housed in a room under controlled temperature (22 \pm 2 $^{\circ}$ C) and lighting (12-h light/dark cycle) conditions, and were treated with a standard pellet diet (Ahvaz Jondi Shapour University of Medical Science, Iran). All the animals were fed ad libitum with normal rat chow and free access to water. After 1 week acclimation, the animals were weighed and divided randomly into five equal groups. All the rats with exception of the control group were injected by 2mg/kgBW.SC of 17 α -ethinylestradiol over 10 consecutive days. Simultaneously, three of estradiol treated groups were given 250, 500, and 1000mg/kg BW of omega-3 fatty acids for 10 days, respectively. Each 1000mg of a softgel capsule contained 180mg EPA and 120 mg DHA, and the recommended dosages were calculated based on the sum of EPA + DHA. At the end of the 10 days treatment, the rats were anaesthetized under chloroform (Merck, Germany) following 12h fasting, and blood samples were finally collected by cardiac puncture.

The plasma was obtained by centrifuging the blood at 4000 rpm for 10 min and stored frozen at -70 \pm 10 $^{\circ}$ C until it was analyzed (EDTA used as anticoagulant). The aspartate aminotransferase (AST) and alanine aminotransferase (ALT) activities were colorimetrically determined according to the procedures described by Ziestchimi, Tehran, Iran (first described by Bergmeyer and Harder, 1986). TNF α were measured using the immunosorbent Elisa commercial kit.

Regarding the histological studies, approximately one half of the liver was fixed in 10% formalin overnight, washed with PBS, and then embedded in paraffin. The liver tissues were subjected to the normal routine histological procedures, stained with Hematoxylin-Eosin and then examined using the light microscope to inspect lipid accumulation and morphological changes. Another portion of the liver was sent to the frozen section and stained with Oil Red O to visualize hepatic fat (Luna., 1968). The whole

procedure for the tissue preparation was carried out at the department of pathobiology, veterinary medicine faculty, Shahid Chamran University of Ahvaz, Iran.

Statistical Analysis: For each parameter considered, the statistical analysis was conducted using one way ANOVA among groups followed by the post-hoc Tukey test. The alpha in all cases was considered to be 5% ($p < 0.05$).

Results

Light microscopic analysis of the liver slices taken from the 17 α -ethinyl estradiol group showed signs of micro vesicular steatosis with fat droplets in all animals (Figure 1A, A*). On the other hand, the group that had received 250mg of omega-3, showed micro vesicular steatosis but less severe than that of the estradiol group (Figure 1B, B*). The liver slices with 500 to 1000 mg of omega-3 showed the typical hepatic architecture (Figure 1C, C*).

As shown in Table 1, in the ethinylestradiol group, the plasma levels of ALT, AST and TNF significantly increased compared to the control group ($p < 0.05$). On the other hand, the rats which were given 1000mg/kg of omega-3, the plasma levels of ALT and TNF- significantly decreased compared to the 17 α -ethinyl estradiol group, ($p < 0.05$), while the doses of 250 and 500mg/kg omega-3 had no significant effect ($p > 0.05$).

The doses of 500 and 1000mg/kg of omega-3 significantly reduced the plasma level of AST in comparison to the 17 α -ethinyl estradiol group, ($p < 0.05$).

Discussion

Discussion Nonalcoholic Fatty Liver Disease (NAFLD) is increasingly recognized as a major health issue and probably the most common of all liver disorders (Harison et al., 2003; Neuschwander-Tetri et al., 2003). NAFLD includes a spectrum of diseases ranging from simple steatosis through nonalcoholic steatohepatitis (NASH) to end-stage liver disease (cirrhosis) (Harison et al., 2003; Preedy et al., 1998). In the present study, we sought to mimic the hepatic fatty acid accumulation and symptomatological aspects of the early stages of fatty liver disease. NASH is a slowly progressive disease

Table 1. Serum biochemical parameters (Mean \pm SEM) of hepatosteatotic rat treated with omega-3 fatty acids. Non similar letters in each column show significantly different ($p < 0.05$).

	TNF α (pg/l)	ALT (IU/l)	AST (IU/l)
Control	102.11 \pm 2.75 ^a	31.75 \pm 2.62 ^a	51.32 \pm 0.93 ^a
Ethinyl estradiol	146.36 \pm 2.93 ^b	82.71 \pm 3.35 ^b	134.32 \pm 9.83 ^b
250mg omega-3	163.64 \pm 7.41 ^b	78.50 \pm 6.53 ^b	122.33 \pm 4.55 ^b
500mg omega-3	161.08 \pm 10.04 ^b	68.25 \pm 4.16 ^b	78.07 \pm 8.43 ^{ac}
1000mg omega-3	117.89 \pm 2.89 ^a	45.67 \pm 2.46 ^a	73.87 \pm 4.09 ^{ac}

characterized by fat accumulation in hepatocytes, mixed cell-type inflammation, focal necrosis, and occasional fibrosis. This disease has been observed worldwide, and the prevalence of NASH is estimated to be 2-3% of the general population (Daniel., 2005).

Animal models are not only useful in revealing the etiology of NASH, but also are important platforms for the assessment of therapeutic strategies (Dasi et al., 2005). In the present study, histological evidence demonstrated that 17 α -ethinylestradiol administration to female wistar rats for 10 consecutive days induced hepatic micro vesicular steatosis (Figure 1A, A*). The high levels of Plasma ALT and AST in the treated animals supported this outcome. These aminotransferases are a marker of hepatic injury in rat (Preedy et al., 1998). Induced hepatosteatosis in our experiment is in accordance with the steatotic model, which has been previously described by Daniel et al., (2005) in female wistar rats (Daniel., 2005).

Although the exact mechanism of estradiol-induced hepatosteatosis in this study is not identified, the high plasma level of TNF α in the ethinyl estradiol-treated group as well as the increased levels of amino-transferases justifies a possible role for TNF α -mediated hepatic injury. In this regard, previous evidence have demonstrated that TNF α : (a) produces oxygen free radicals due to respiratory chain disturbance which in turn induces lipid peroxidation and tissue injuries (Preedy et al., 1998), (b) increases fatty acid synthesis which could be used for the liver TG production, and (c) induces insulin resistance (El-badry et al., 2007). Overall, these properties may predispose liver to hepatosteatosis.

In this study, the systematic decrease of ALT and AST plasma level accompanied by reduced hepatic injuries, due to doses of 500 and 1000 mg/kg omega-3 fatty acids indicate the preventive effect of these fatty acids, in a dose dependent manner. The dose of

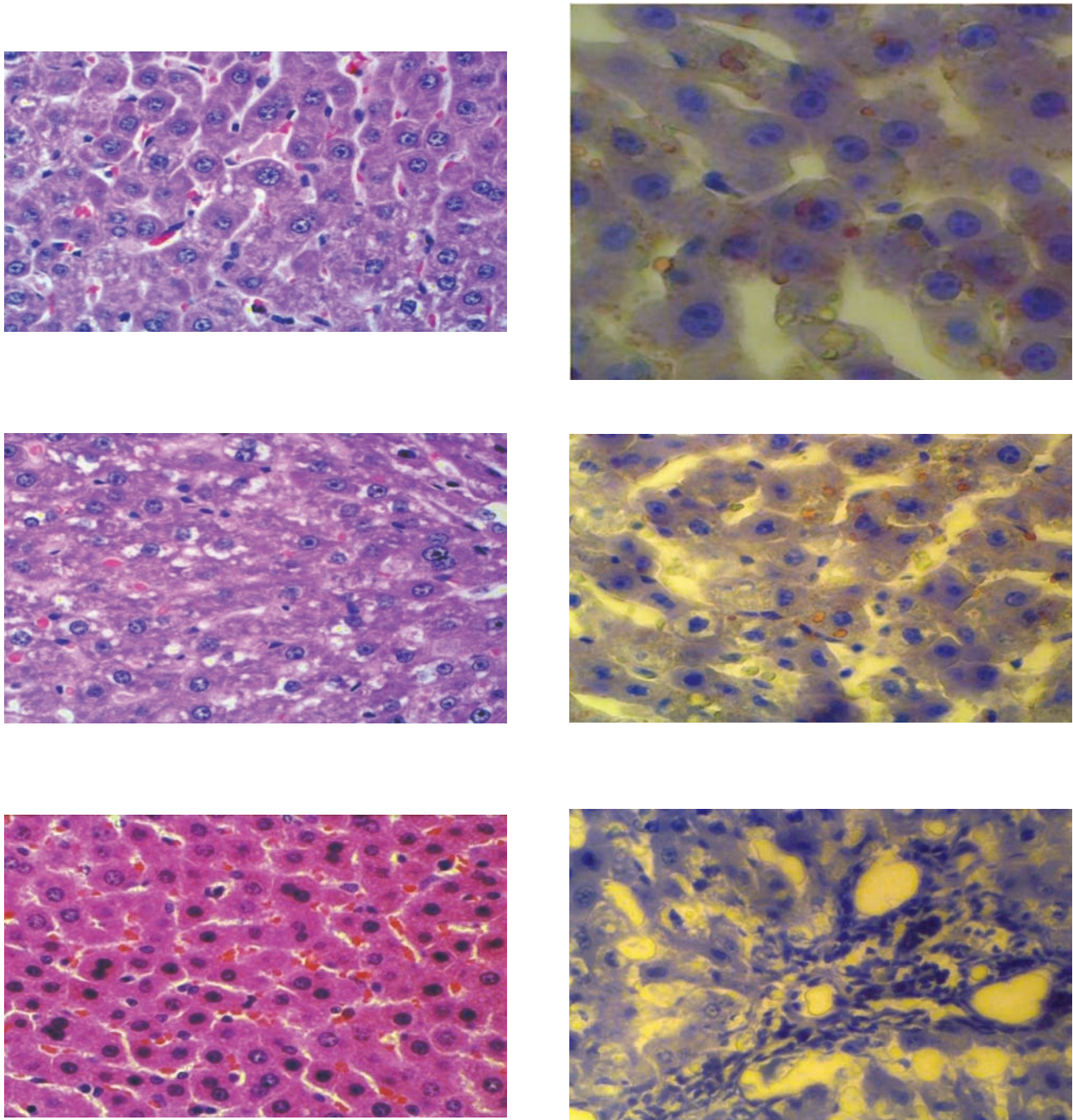


Figure 1. light microscopic analysis of a section of liver slices taken from the ethinylestradiol group stained with H&E (A) and Oil Red O (A), and from the 250mg/kg omega-3 treated group (B,B), and 1000mg/kg omega-3 treated group (C, C*). White vacuole in H&E and red Vacuole in Oil red O staining show microvesicular fatty change.

250mg/kg had no effect while the maximum effect was produced by a dose of 1000mg/kg (Figures 1C, C*). Omega-3 fatty acids have hypolipidemic (Ian et al., 2005; Teran-Garcia et al., 2007), anti-inflammatory and antioxidant effects and have shown that they could positively affect NAFLD patients (Hao et al., 2010; Vanwerven et al., 2010). They reduce

lipogenic enzymes' activity in the liver (Demoz et al., 1992), inhibit lipid peroxidation (Barbosa et al., 2003; Erdogan et al., 2004; Iraz et al., 2005), and decrease TNF- secretion (Hao et al., 2010). In this study, the plasma level of TNF- in the 1000mg/kg of omega-3 treated group showed a significant decrease in comparison to that in the ethinyl estradiol group.

This finding that proves hepatoprotective effect of omega-3 fatty acids is in part due to the anti-inflammatory effect. However, the other mechanism also may be involved.

The key finding of this work is that omega-3 fatty acid (1000 mg/kg) has protecting features against the hepatostatic manifestations induced by a 10-day treatment with ethinyl estradiol in female wistar rats.

We have demonstrated that SC supplementation of 1000mg/kg/day O3FAs can ameliorate hepatic steatosis in the ethinyl stradiol rat model.

Acknowledgments

This research was part of a the D.V.M. thesis and financially supported by Shahid Chamran University, Ahvaz, Iran. All involved in this work are highly appreciated by the authors.

References

1. Abraham, S., Hillyard, L.A., Hansen, F.N., Lin, C.Y. (1980) Tissue specificity for the effect of estrogen on lipogenic activity in male and female rats. *lipids and lipid metabolism, Bichem Biophys Acta.* 6: 167-171.
2. Adam, L.A., Angulo, P. (2006) Treatment of nonalcoholic fatty liver disease. *Postgrad Med J.* 82: 315-322.
3. Barbosa, D.S., Cecchini, R., El Kadri, M.Z., Burini, R.C. (2003) Decreased oxidative stress in patients with ulcerative colitis supplementation with fish oil fatty acids. *Nutrition.* 19: 837-842.
4. Bouchard, G., Yousef, I.M., Tuchweber, B. (1993) Influence of oral treatment with ursodeoxycholic and tauroursodeoxycholic acids on estrogen-induced cholestasis in rats: effects on bile formation and liver plasma membranes. *Liver.* 13: 193-202.
5. Carl, M.O., Jean-François, D. (2002) Non-alcoholic fatty liver disease: treatment options based on pathogenic considerations. *Swiss Med Wkly.* 132: 493-505.
6. Clark, J.M., Brancati, F.L., Diehl, A.M. (2002) Nonalcoholic fatty liver disease. *Gastroenterology.* 22: 1649-1657.
7. Daniel, Y.H., Gerhard, A.S., Chang, P., Burczynski, F.J., Roberts, M.S. (2005) Reduced hepatic extraction of palmitate in steatosis correlated to lower level of liver fatty acid binding protein. *Am J Physiol.* 288: G93-G100.
8. Das, K., Kar, P. (2005) Non-alcoholic steatohepatitis. *J Assoc Physicians India.* 53: 195-199.
9. Day, C., James, O. (1998) Steatohepatitis: A tale of two "hits". *Gastroenterology.* 114: 842-845.
10. Demoz, A., Willumsen, N., Berge, R.K. (1992) Eicosapentaenoic acid at hypotriglyceridemic dose enhances the hepatic antioxidant defence in mice. *Lipids.* 27: 968-971.
11. El-Badry, A.M., Graf, R., Clavien, P.A. (2007) Omega 3-Omega 6: what is right for the liver?. *J Hepatol.* 47: 718-725.
12. Endo, M., Masaki, T., Seike, M., Yoshimatsu, H. (2007) TNF- α induces hepatic steatosis in mice by enhancing gene expression of sterol regulatory element binding protein-1c (SREBP-1c). *Exp Biol Med.* 232: 614-621.
13. Erdogan, H., Fadillioglu, E., Ozgocmen, S., Sogut, S., Ozyurt, B., Akyol O., et al. (2004) Effect of fish oil supplementation on plasma oxidant/ antioxidant status in rats. *Prostaglandins Leukot Essent Fatty Acids.* 71: 149-152.
14. Hao, W., Wong, O.Y., Liu, X., Lee, P., Chen, Y., Wong, K.K. (2010) ω -3 fatty acids suppress inflammatory cytokine production by macrophages and hepatocytes. *J Paediatr Surg.* 45: 2412-2418.
15. Haque, M., Sanyal, A.J. (2002) The metabolic abnormalities associated with nonalcoholic fatty liver disease. *Best Pract Res Clin Gastroentero.* 16: 709-713.
16. Harrison, S.A., Di Bisceglie, A.M. (2003) Advances in the understanding and treatment of nonalcoholic fatty liver disease. *Drugs.* 63: 2379-2394.
17. Ian, P.J., Gura, K., Nosé, V., Zausche, B., Javid, P., Garza, J., et al. (2005) Omega-3 fatty acid supplementation prevents hepatic steatosis in a murine model of nonalcoholic fatty liver disease. *Pediatr Res.* 57: 445-452.
18. Iraz, M., Erdogan, H., Ozyurt, B. (2005) Brief communication: omega-3 essential fatty acid supplementation and erythrocyte oxidant/antioxidant status in rats. *Ann Clin Lab Sci.* 35: 169-173.
19. Jesus, M., Luis, I. (2004) Approach to the Pathogenesis and Treatment of Nonalcoholic Steatohepatitis. *Diabetes Care.* 27: 2057-2066.
20. Kajikawa, S., Harada, T., Kawashima, A., Imada, K., Mizuguchi, K. (2009) Highly purified eicisapent-

- aeoic acid ethyl ester prevents development of steatosis and hepatic fibrosis in rat. *Dig Dis Sci.* 32: 130-141.
21. Luna, L.G. (1968) *Manual of Histologic Methods of the Armed Forces Institute of Pathology.* (3rd ed.). McGraw-Hill Book Company, Toronto. p. 39-89.
 22. Neuschwander-Tetri, B.A., Caldwell, S.H. (2003) Nonalcoholic steatohepatitis: summary of an AASLD Single Topic Conference. *Hepatology.* 37: 1202-1219.
 23. Preedy, V.R., Reily, M.E., Mantte, O., Peters, T.J. (1998) Oxidative damage in liver disease. *J Int Fed Clin Chem.* 10: 16-19.
 24. Teran-Garcia, M., Adamson, A.W., Yu, G., Rufo, C., Suchankova, G., Dreesen, T.D., et al. (2007) Polyunsaturated fatty acid suppression of fatty acid synthase (FASN): evidence for dietary modulation of NF- κ B binding to the Fasn promoter by SREBP-1c. *Biochem J.* 402: 591-600.
 25. Van Werven, J.R., Schreuder, T.C., Nederveen, A.J., Lavini, C., Jansen, P.L., Stoker, J. (2010) Hepatic unsaturated fatty acids in patients with non-alcoholic fatty liver disease assessed by 3.0T MR spectroscopy. *Eur J Radiol.* 75: e102-e107.

اثر محافظتی اسیدهای چرب امگا-۳ بر هیپاتو استئاتوز القاء شده توسط اتینیل استرادیول در رتهای ماده

مرجان چهارده چریک^۱ علی شهریاری^{۱*} پیمان اسدیان^۲ صالح اسماعیل زاده^۳

(۱) گروه علوم پایه، دانشکده دامپزشکی دانشگاه شهید چمران اهواز، اهواز- ایران

(۲) گروه علوم درمانگاهی، دانشکده دامپزشکی دانشگاه لرستان، خرم آباد- ایران

(۳) گروه پاتوبیولوژی، دانشکده دامپزشکی دانشگاه شهید چمران اهواز، اهواز- ایران

(دریافت مقاله: ۱۸ بهمن ماه ۱۳۹۱، پذیرش نهایی: ۲۶ فروردین ماه ۱۳۹۲)

چکیده

زمینه مطالعه: لاستئاتوز کبدی ناشی از استروژن درمانی سبب افزایش فعالیت شاخص های التهاب به ویژه TNF- α می شود که به نوبه خود روند لیپوژنز کبدی را تشدید می کند. اسیدهای چرب امگا-۳ لیپوژنز را تعدیل می کنند. در این پژوهش اثر پیشگیری کننده اسیدهای چرب امگا-۳ بر هیپاتو استئاتوز القایی توسط استروژن بررسی شده است. **روش کار:** ۲۵ سررت ماده نژاد ویستار در ۵ گروه مساوی روزانه ۲mg/kg از (17 α -ethinyl estradiol) به استثناء گروه کنترل) را به صورت زیر پوستی به مدت ۱۰ روز دریافت کردند. همزمان سه گروه از رت ها به ترتیب یکی از دوزهای ۲۵۰mg/kg، ۵۰۰ و ۱۰۰۰mg/kg اسید چرب امگا-۳ را بصورت خوراکی دریافت کردند. در پایان آزمایش سطح پلاسمایی AST، ALT، و TNF- α تعیین و نیز نمونه های کبدی با رنگ آمیزی H&E و OilRed مطالعه شدند. **نتایج:** یافته های هیستولوژیکی هیپاتو استئاتوز میکروویژیکولار و نیز تجمع چربی را در گروه اتینیل استرادیول و به مقدار کمتر در گروه ۲۵۰mg/kg اسید چرب امگا-۳ نشان داد. سطوح پلاسمایی AST، ALT، و TNF- α در گروه اتینیل استرادیول بطور معنی داری بیشتر از گروه کنترل بود ($p < 0.05$) و دوز ۱۰۰۰mg/kg اسید چرب امگا-۳ سبب کاهش معنی دار این پارامترها نسبت به گروه اتینیل استرادیول شده بود ($p < 0.05$). **نتیجه گیری نهایی:** این یافته ها نشان داد که دوز ۱۰۰۰mg/kg اسید چرب امگا-۳ کبد را از ضایعات استئاتوزی اتینیل استرادیول محافظت می کند.

واژه های کلیدی: هیپاتو استئاتوز، رت، اتینیل استرادیول، آسپارات آمینوترانسفراز، آلانین آمینوترانسفراز

(* نویسنده مسؤول: تلفن: ۳۳۳۰۰۷۳ (۶۱۱) ۹۸+، نمابر: ۳۳۶۰۸۰۷ (۶۱۱) ۹۸+ Email: a.shahriari@scu.ac.ir