

Immunization of lambs against infection with *Echinococcus Granulosus* using protoscolices and hydatid fluid antigens

Hashemitabar, GH. R.^{1*}, Razmi, GH. R.¹, Naghibi, A.¹

¹Department of Pathobiology, School of Veterinary Medicine, Ferdowsi University of Mashhad, Mashhad-Iran.

(Received 28 August 2005 , Accepted 11 December 2006)

Abstract: In the present study, protoscolices and hydatid fluid were prepared from livers or lungs of sheep with hydatid cyst in sterile conditions. The protein concentration of samples was then measured by Bradford method. 12 lambs 4 - 6 months of age of mixed sex were randomly allocated to 3 groups of 4 lambs. Each lamb in groups 1 and 2 was immunized subcutaneously in the neck with a 2 - ml dose of vaccine (1 mg of protoscolex and hydatid fluid proteins dissolved in 1 ml of PBS) and emulsified with an equal volume of Freund's complete adjuvant (FCA) respectively. Control lambs were immunized with adjuvant in PBS. Lambs were boosted at day 28 with the same preparation except that FCA was replaced by Freund's incomplete adjuvant (FIA). Three weeks after the second immunization, each lamb received a challenge infection with 2000 protoscolices intraperitoneally and 10 adult *E. granulosus*. All lambs were euthanized after 7 months and examined for hydatid cysts. Results showed that, the number of cysts in immunized lambs with protoscolices were lower than in control group and also the number of cysts in immunized lambs with hydatid fluid antigen was significant ($p < 0.05$). This result indicated that the protective immunity in lambs with protoscolices and hydatid fluid was 54.5% and 75.75% respectively.

Key words: *Echinococcus granulosus*, protoscolex, hydatid fluid, immunization, lamb.

Introduction

Hydatidosis is the parasitization of tissue by the larval stage of different cestodes of the *Echinococcus* genus and represents a public health problem with important economic implications (Gadea *et al.*, 1999).

Hydatid disease is a common terminology for cysts of the dog tapeworm parasite. Cysts slowly grow in grazing animals that have eaten eggs of the tapeworm. Those eggs become infective to the dogs after 2-5 years. The life-cycle is completed when dogs eat infective cysts. Sheep become infected with the tapeworm eggs, and suffer hydatid disease (Heath *et al.*, 2003). Although many species of domestic livestock and herbivorous wildlife species are potential hosts for *E. granulosus*, sheep play a major

role in transmission of the parasite globally (Lightowers *et al.*, 1999). This parasite can potentially occur all over the world specially in Mediterranean and Middle East countries and some parts of Africa, Latin America and China which have major focus on human infections. New areas of infection are being reported, giving to Echinococcosis the status of an emerging zoonosis (Eckert *et al.*, 2000).

The long-term evaluation of various control strategies against *E. granulosus* has produced a large amount of data, providing a scientific basis for the improvement of control schemes. A new option for the control of *E. granulosus* in the intermediate host population (mainly sheep and cattle) is vaccination (Eckert and Deplazes, 2004).

A vaccine candidate for the intermediate host has been tested in sheep, showing a high degree of

* Corresponding author's email: hashemitabar@um.ac.ir, Tel: 0511- 8763852, Fax: 0511- 8763852



protection (Lightowlers *et al.*, 1996; 1999; 2000; Woollard *et al.*, 1998).

Materials and Methods

Preparation of Samples:

Hydatid fluid was isolated from livers or lungs of sheep with hydatid cyst in sterile conditions. Hydatid fluid was centrifuged at 5000 g for 30 min (4°C) to remove protoscolices and stored at -20°C until used. Isolated protoscolices were washed with Hank's solution for three times. The suspension was subjected to 3 cycles of freeze/thaw as follows: the tube was frozen in liquid nitrogen and thawed at 42°C, this cycle was repeated 2 more times. The suspension then mixed with four volumes of PBS, PH 7.4, containing sodium azide at 0.1 mg/ml. The sample was then sonicated in a 170 W ultrasonic for 3x15 sec pulses on ice at a high output setting until no intact protoscolices were visible. The preparation centrifuged for 30 min at 10,000 g and then filtered (0.22 µm) and stored at -20°C until used.

Protein Concentration and Dialysis:

Protein concentration of protoscolex and hydatid fluid samples was determined as described by Bradford (1976). In the case of low concentration, samples were dialyzed. The dialysis membrane (Millipore) was boiled for 5 min to remove a variety of chemicals introduced during manufacture. Enough space was left for expansion and the tubing was then closed with a knot at the top and concentrated by dialysis tube (cut off 12000 Da) and with polyethylenglycol (20000Da).

Immunization:

In this study, 12 lambs 4-6 months of age and also of mixed sex, were randomly allocated to 3 groups of 4 lambs. Each lamb in groups 1 and 2 was immunized subcutaneously in the neck with a 2 ml dose of vaccine (1 mg of protoscolices and hydatid fluid proteins dissolved in 1 ml of PBS) and emulsified with an equal volume of Freund's complete adjuvant (FCA) respectively. Control lambs were immunized with a total volume of 2 ml of adjuvant in PBS. Lambs were boosted at day 28 with the same preparation

Table I: Numbers of hydatid cysts in immunized and control groups of lambs.

Groups	No. of cysts in individual lambs				Mean ± SD
Control	12	12	7	2	8.2 ± 4.7
Protoscolices	4	2	3	6	3.7 ± 1.7
Hydatid fluid	1	5	1	1	*2 ± 2

*Significantly different from control group by Student's t-test (p<0.05).

except that FCA was replaced by Freund's incomplete adjuvant (FIA).

Challenge:

Twenty-one days after the second immunization each lamb was challenged with 2000 protoscolices intraperitoneally and also with 10 gravid individuals of *E. granulosus* as described by Lightowlers *et al.* (1999). Worms were injected into the rumen via a 16G 10-cm syringe needle fitted with a disposable three-way stopcock. Prior to injection of the worms, a small amount of water was injected into the rumen via a second syringe connected to the stopcock and the fluid was immediately withdrawn to ensure that rumen contents were visible, indicating correct placement of the needle. After injection of the worms, the needle was flushed with approximately 20 ml water via a second syringe also fitted to the stopcock. This method ensured the delivery of the same dose of infective worms into the rumen of each lamb and prevented any possibility of contamination of the operators with *E. granulosus*.

Approximately 7 months after the experimental infection, the lambs were euthanized and examined for hydatid cysts. The carcasses were dressed and internal organs examined superficially for the presence of hydatid cysts. The heart and kidneys were sliced and the omentum and spleen were also examined. The liver and lungs were examined extensively. The liver was sliced at intervals of approximately 3 mm. The lungs were sliced at intervals of approximately 6-8 mm and palpated.

Measurement of Protective Immunity

In this study, protective immunity in lambs was determined with the method described by Dempster *et al.*, (1995) which is as follows:

% protective immunity in vaccinated animals =



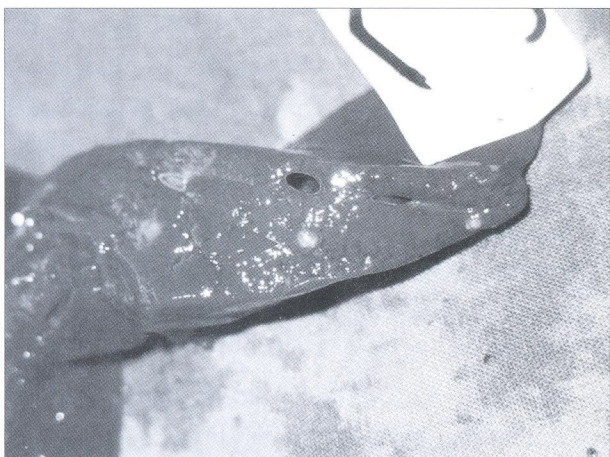


Figure 1: Hydatid cysts in the liver of sheep in control group.

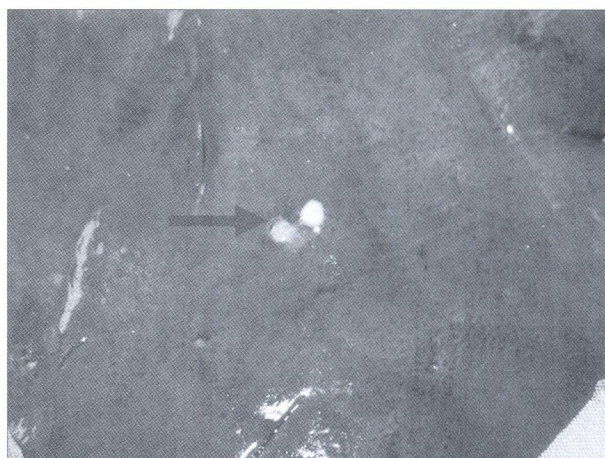


Figure 2: Hydatid cysts in the liver of sheep in immunized group.

$$\frac{1 - \text{average NO. of cysts in test group}}{\text{average NO. of cysts in control group}} \times 100$$

Statistical Analysis:

The results of these experiments were analyzed by Student's t-test. P values of 0.05 or lower were considered significant.

Results

After 7 months, all lambs were slaughtered and their internal organs were searched carefully for hydatid cysts. Results showed that in immunized lambs with protoscolices and also with hydatid fluid antigens, hydatid cysts either were not observed, or in comparison with the control group, smaller cysts with lower numbers were observed. The average size of hydatid cysts in hydatid fluid, protoscolex and

control groups were 3.1 mm, 3.6 mm and 9.5 mm, respectively. The number of hydatid cysts in protoscolex (Fig. 4), hydatid fluid (Fig. 3) and control groups (Fig. 1, 3) were 15, 8 and 33, respectively (Table 1). The mean numbers of hydatid cysts in protoscolex, hydatid fluid and control groups were 3.7, 2 and 8.2, respectively. In this study, protective immunity in lambs immunized with protoscolex and hydatid fluid were 54.5% and 75.75% respectively (Table 1) and the result which was obtained in hydatid fluid group was significant ($p < 0.05$).

Discussion

A range of different antigens including cyst fluid (De Rosa *et al.*, 1977; Dada and Belino 1981; Heath *et al.*, 1992) and protoscolex antigen (Hernandez and Nieto, 1994) has been used as prototype vaccines

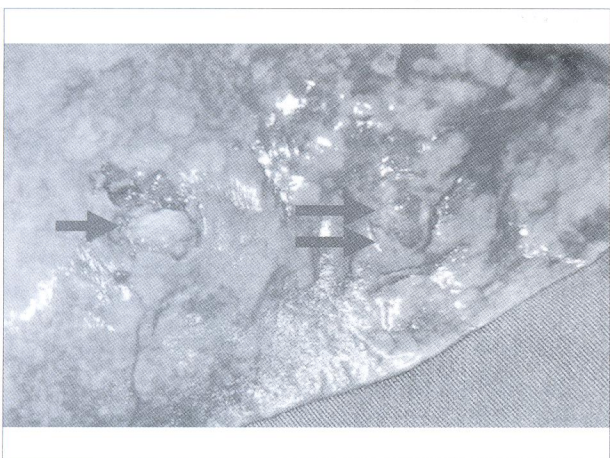


Figure 3: Hydatid cysts in the lung of sheep in control group.

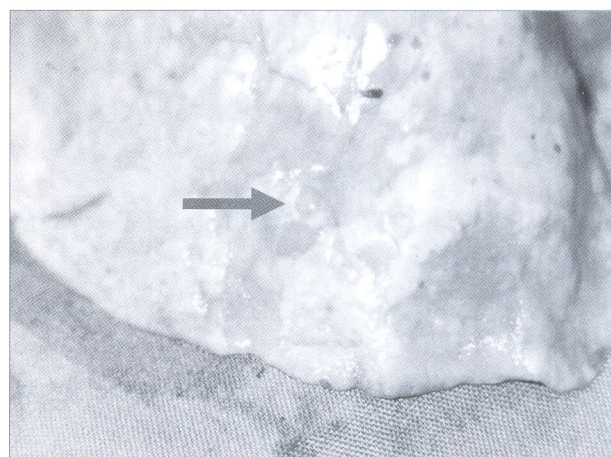


Figure 4: Hydatid cysts in the lung of sheep in immunized group.



against *E. granulosus*. A mouse model has been developed to evaluate potential protective antigens which could render intermediate hosts resistant to a challenge infection with *Echinococcus granulosus* eggs (Dempster *et al.*, 1991).

We used lambs to evaluate resistance against subsequent challenge following vaccination with protoscolices antigen and hydatid cyst fluid. Haghpanah *et al.*, (2003) reported that the protective immunity induced with protoscolices in mice was 76.6-79.7 percent. Results of this study showed that surface protein of protoscolices emulsified in Freund incomplete adjuvant probably can be used for immunization of intermediate host in future. Molan and Saeed (1988) immunized mice against *E. granulosus* secondary infection with protoscolices, by injecting protoscolices subjected to ultraviolet irradiation. The best results were obtained when the protoscolices used for vaccination were damaged but not killed by the irradiation. Stagni *et al.*, (1986), using a model of Balb/c mice infected with secondary *E. granulosus* cysts by transplantation, found that immunization with ammonium sulphate fraction of protoscolices had an inhibitory effect on the growth of cysts.

Acknowledgements

The authors thank Dr. Rajabiyoun, Dr. Sardari and Mr. Azari for affording their time and help. We also thank to the Ferdowsi University of Mashhad for financial support.

References

- Bradford, M. M. (1976) A rapid and sensitive method for the quantitation of microgram quantities of protein utilizing the principle of protein-dye binding. *Anal Biochem.* 72: 248-254.
- Dada, B. J., Belino, E. D. (1981) Immunization of sheep against cystic hydatidosis with homologous and heterologous metacestode antigens. *Int. J. Zoonoses.* 8: 20-25.
- Dempster, R. P., Berridge, M. V., Harrison, G. B., Heath, D. D. (1991) *Echinococcus granulosus*: development of an intermediate host mouse model for use in vaccination studies. *Int. J. Parasitol.* 2: 549-554.
- Dempster, R. P., Harrison, G. B. L., Berridge, M. V. (1995) Maternal transfer of protection from *Echinococcus granulosus* infection in sheep. *Res. Vet. Sci.* 58: 197-202.
- De Rosa, F., Dottorini, S., Pauluzzi, S. (1977) Vaccination against experimental peritoneal hydatid disease of BALB/C mice with hydatid fluids and their fractions. *Ann. Sclavo.* 19: 470-477. (In Italian.)
- Eckert, J., Conraths, F., Tackmann, K. (2000) Echinococcosis: an emerging or re-emerging zoonosis? *Int. J. Parasitol.* 30: 1283-94.
- Eckert, J., Deplazes, P. (2004) Biological, epidemiological, and clinical aspects of echinococcosis, a zoonosis of increasing concern. *Clin. Microbiol. Rev.* 17: 107-35.
- Gadea, I., Ayala, G., Diago, M. T., Cunat, A., De Lomas, J. G. (1999) Immunological diagnosis of human cystic echinococcosis: utility of discriminant analysis applied to the enzyme-linked immunoelectrotransfer blot. *Clin. Diagn. Lab. Immunol.* 6: 504-508.
- Heath, D. D., Lawrence, S. B., Yong, W. K. (1992) *Echinococcus granulosus* in sheep: transfer from ewe to lamb of "Arc 5" antibodies and oncosphere-killing activity, but not protection. *Int. J. Parasitol.* 22: 1017-1021.
- Heath, D. D., Jensen, O., Lightowers, M. W. (2003) Progress in control of hydatidosis using vaccination--a review of formulation and delivery of the vaccine and recommendations for practical use in control programmes. *Acta Trop.* 85: 133-43.
- Haghpanah, B., Ghayour, Z., Ahmady, N., Hejazy, H. (2003) *E. granulosus* infection in mice following immunization with protoscolices antigens. 4th National Iranian Congress of Parasitology and Parasitic Diseases. Mashhad, Iran.
- Hernandez, A., Nieto, A. (1994) Induction of protective immunity against murine secondary hydatidosis. *Parasite. Immunol.* 16: 537-544.



13. Lightowlers, M. W., Lawrence, S. B., Gauci, C. G., Young, J., Ralston, M. J., Maas, D. and Heath, D. D. (1996) Vaccination against hydatidosis using a defined recombinant antigen. *Parasite Immunol.* 18:457-462.
14. Lightowlers, M. W., Jensen, O., Fernandez, E., Iriarte, J. A., Woollard, D. J., Gauci, C. G., Jenkins, D. J. and Heath, D. D. (1999) Vaccination trials in Australia and Argentina confirm the effectiveness of the EG95 hydatid vaccine in sheep. *Int. J. Parasitol.* 29: 531-534.
15. Lightowlers, M. W., Flisser, A., Gauci, C. G., Heath, D. D., Jensen, O. and Rolfe, R. (2000) Vaccination against cysticercosis and hydatid disease. *Parasitol. Today.* 16: 191-196.
16. Molan, M., Saeed, I. (1988) Protection of mice against *Echinococcus granulosus* by previous inoculation with protoscoeces exposed to ultraviolet irradiation. *Jpn. J. Parasitol.* 37: 203-208.
17. Stagni, G., Baldelli, F., Tassi, C., Papili, R., Moretti, M., Di, C. F., Francisci, D. and Candilo, F. D. (1986) Experimental peritoneal hydatid infection by transplantation in Balb/c mice: chemotherapy and immunotherapy. *Parassitologia.* 28: 360-362.
18. Woollard, D. J., Gauci, G. G., Heath, D. D., Lightowlers, M. W. (1998) Epitope specification and antibody response to the EG95 hydatid vaccine. *Parasite. Immunol.* 20:535-540.



ایمن سازی بره ها علیه اکینو کوکوس گرانولوزوس با استفاده از پروتواسکولکسها و مایع هیداتید

غلامرضا هاشمی تبار^{۱*}، غلامرضا رزمی^۱، ابوالقاسم نقیعی^۱
^۱گروه پاتوبیولوژی دانشکده دامپزشکی، دانشگاه فردوسی مشهد، مشهد-ایران.
 (دریافت مقاله: ۲۱ شهریورماه ۱۳۸۴، پذیرش نهایی: ۲۰ آذرماه ۱۳۸۵)

در مطالعه حاضر، پروتواسکولکسها و مایع هیداتید از کبد و ریه های گوسفندان مبتلا به کیست هیداتید در شرایط استریل جدا گردید. غلظت پروتئینی نمونه ها با استفاده از روش برادفورد اندازه گیری شد. ۱۲ بره ۶-۴ ماهه از جنس نر و ماده به طور تصادفی به سه گروه چهار تایی تقسیم شدند. هر یک از بره های گروه ۱ و ۲ (گروه های آزمایش) به ترتیب با یک میلی گرم پروتواسکولکس و مایع هیداتید حل شده در یک میلی لیتر بافر فسفات همراه با یک میلی لیتر ادجوانت کامل فروند ایمن نیزه شدند. بره های گروه کنترل با مخلوط بافر فسفات و ادجوانت کامل فروند ایمن نیزه شدند. چهار هفته بعد تمام بره ها دوباره مورد تزریق قرار گرفتند با این تفاوت که از ادجوانت ناقص فروند استفاده گردید. سه هفته پس از تزریق دوم، هر بره با ۲۰۰۰ عدد پروتواسکولکس از طریق داخل صفاقی و نیز ۱۰ عدد انگل بالغ از طریق شکمبه مورد چالش قرار گرفتند. تمام بره ها ۷ ماه پس از چالش کشتار شده و اندامهای داخلی آنها از نظر وجود کیست هیداتید مورد بررسی قرار گرفتند. نتایج نشان داد که تعداد کیستهای هیداتید در بره های ایمن شده با پروتواسکولکسها و نیز مایع هیداتید کمتر از گروه کنترل بوده و اختلاف کیستها در گروه ایمن شده با مایع هیداتید و کنترل معنی دار بود ($p < 0.05$). میزان ایمنی حفاظتی در این مطالعه در بره ها به ترتیب بوسیله پروتواسکولکسها و مایع هیداتید ۵/۵۴ و ۷۵/۷۵ درصد بود.

واژه های کلیدی: اکینو کوکوس گرانولوزوس، پروتواسکولکس، مایع هیداتید، ایمن سازی، بره.

