

Comparison of computerized digital and analog radiography for detection of bronchial pattern in dogs

Tavakoli, A.¹, Vajhi, A.^{1*}, Molazem, M.¹, Soroori, S.¹, Rostami, A.², Hasankhani, M.², Faskhoodi, D.¹

¹Department of Surgery and Radiology, Faculty of Veterinary Medicine, University of Tehran, Tehran, Iran

²Department of Internal Medicine, Faculty of Veterinary Medicine, University of Tehran, Tehran, Iran

Keywords:

Analog, bronchial pattern, digital, dog, radiography

Correspondence

Vajhi, A.

Department of Surgery and Radiology, Faculty of Veterinary Medicine, University of Tehran, Tehran, Iran

Tel: +98(21) 61117120

Fax: +98(21) 66438327

Email: avajhi@ut.ac.ir

Received: 11 November 2016

Accepted: 17 February 2017

Abstract:

BACKGROUND: Analog radiography has been replaced with digital radiography for canine diagnostic imaging in many veterinary clinics. There is no data comparing these modalities in a veterinary clinical setting to detect bronchial pattern signs in dogs. **OBJECTIVES:** In this study, computerized digital radiography (CR) and analog radiography were compared for diagnosis of bronchial pattern in dogs. **METHODS:** Forty-five healthy (based on clinical examination and history taking) mixed breed dogs were divided into 3 age groups: up to two, two-six and more than 6 years old. Each group contained fifteen dogs. DR and FSR in right to left lateral (RL) and ventrodorsal (VD) views were taken. Two expert radiologists interpreted the radiographs based on counting bronchial ring and tram line signs in a double blinded scheme. **RESULTS:** The statistical analysis of results, with Sign Test, shows that more bronchial ring and tram-like signs were counted with both radiologists using digital radiography. In addition, countable bronchial signs on right lateral position by digital and analog radiography were significantly more than in ventrodorsal view. In comparison with analog images, a greater number of bronchial ring and tram-like signs are associated with greater diagnostic confidence in digital modality. **CONCLUSIONS:** This study shows superior ability of digital radiography for detecting details in thoracic radiography of normal dogs in comparison with analog radiography. Since digital radiography is getting to be more commonly used by veterinary practitioners, it is necessary to understand the shortcomings of current classification of pulmonary pattern approach in digital radiology.

Introduction

Interpreting thoracic radiographs for pulmonary assessment is challenging. One reason is the excellent radiographic contrast that arises from the large volume of air in the lung which allows numerous small pulmonary structures to be seen radiographi-

cally. In addition, heterogeneity of lung tissue is another reason.

There are a large number of factors that influence the radiographic appearance of the lung for each analog (also named as film screen or conventional) or digital modality. These include radiographic technique, encompassing exposure factors and

type of acquisition hardware, the effect of the position of the patient, effects of recumbent-atelectasis and respiratory phase. Although careful attention to technical detail is important when radiographing all body parts, the complexity of the thorax makes this even more critical (Thrall a, 2013).

For better interpretation of lung radiographs, pulmonary alterations are divided to few patterns in terms of whether they involve primarily the alveoli, the bronchi, the interstitium or the vessels. These patterns indicate microscopic distribution of pathogens through lung tissue (Suter, P.F., Chan, K.F 1968).

Even experienced radiologists often differ among themselves about interpretation of thoracic radiographs. Using a special pulmonary pattern for evaluation of lung radiographs, which indicates whether a compartment of lung involvement has undergone changes following a disease, provides a more accurate identification of pulmonary disease. Some patterns are expectable in special pulmonary abnormalities, causing more precise differential diagnosis (Reeder M. and Felson B. 2003).

The bronchial pattern occurs when the bronchial wall thickness is increased by cellular or fluid infiltration or when air in the immediate peribronchial space has been replaced by cells or fluid. Radiographically, this manifests as an increased number of "ring shadows", created by an end-on relationship between the abnormal bronchus and the primary x-ray beam, or an increased number of parallel lines, called "tram lines", created by a side-on relationship between the abnormal bronchus and the primary x-ray beam.

Bronchial pattern emerges following allergic airway disease, bacterial and fungal

infections, chronic irritations, cardiogenic pulmonary edema and diffuse tumors. In normal conditions, a few rings and tram like shapes may be detected, due to some normal airways being projected directly end-on or side-on, but in a bronchial pattern, the overall number of ring shadows and tram lines will be increased above normal (Thrall 2013 b).

Analog radiography is recently replaced by digital radiography in veterinary diagnostic imaging centers. Digital radiography represents better images due to wider dynamic range, optimization of contrast and brightness and edge enhancement tools. Moreover, digital radiography creates more explicit images of organs in which some parts may super impose on each other such as lung hilus, heart and diaphragm regions (Ganten et al. 2003, Konen et al. 2005).

Drost (2011) stated that advantages of digital radiography compared with analog radiography include improved image quality (when used properly), ease of use (more forgiving of the errors of radiographic technique), speed of completing the study (especially for very ill patients), fewer repeat radiographs, less time looking for imaging studies, less physical storage space and the ability to easily send images for consultation. Because of these advantages transitioning from analog radiography to digital is necessary.

As digital radiography is taking a more prominent role in veterinary medicine, no certain studies exist specifically to evaluate bronchial pattern in dogs using digital and analog radiography. It appears that more total visible bronchi can be detected by digital radiography than analog radiography in healthy dogs, causing bronchial pattern term to be challenging.

Table 1. Mean and standard deviation of recorded bronchi of dogs in right lateral and VD positions by digital and analog techniques.

		Up to 2 years old		years old 2-6		Over 6 years old	
		Radiologist 2	Radiologist 1	Radiologist 2	Radiologist 1	Radiologist 2	Radiologist 1
Right Lateral	Analog	2.47±1.30	1.87±0.83	1.87±1.19	2.93±1.33	2.80±1.70	3.67±1.95
	Digital	4.80±2.93	5.40±2.64	4.07±1.79	5.47±2.47	5.47±3.07	5.53±2.42
Ventrodorsal	Analog	1.67±1.11	1.73±1.53	1.27±1.33	2.13±1.30	1.60±0.91	2.33±1.72
	Digital	2.87±2.06	4.13±2.47	3.67±1.54	5.40±2.82	2.87±2.23	4.60±2.69
Total (Sum of Lateral and VD)	Analog	4.13±1.73	3.60±1.80	3.13±1.92	5.07±1.98	4.40±1.96	6.00±2.82
	Digital	7.67±4.24	9.53±4.29	7.73±3.15	10.87±4.97	8.33±4.85	10.13±3.72

The aim of present study is to compare visibility of bronchial lung pattern using analog and digital radiography in clinically healthy dogs.

Materials and Methods

Forty-five mixed breed dogs were selected. The dogs were carefully clinically and paraclinically examined and there was no clinical respiratory abnormality in selected dogs. They were divided into three age groups (15 dogs/group); younger than 2, 2-6 and older than 6 years of age. Right lateral and Ventrodorsal (VD) analog (specific pulmonary protocol including low milliamper second (mAs) and high kilovoltage (kV) and digital radiograph were conducted for each dog. All images were taken at inspiration. The analog radiography was performed by green-type film (Carestream Health, Inc., U.S.A.). Digital radiography was conducted by CR CLASSIC set (Carestream Health, Inc., U.S.A.). The x-ray machine (DC-12M, Toshiba, Japan) used in this study was the same in analog and digital ones. All images were separately evaluated by experienced radiologists. Digital images were observed by Clear Canvas software. Analog images were evaluated on standard negatoscope. The radiologists were blinded and independent to dog ages and each other's reports.

All visible bronchi were counted through analog and digital images of lateral and VD radiographs separately by each radiologist. Finally, the results of both techniques in lateral and VD views were statistically compared by Sign Test. The frequency of visible bronchi in different age groups was analyzed by Kruskal-Wallis method.

Results

The frequency of visible bronchi through analog and digital techniques revealed that total countable bronchi in digital were statistically more than analog technique in both lateral and VD radiographs by both radiologists (Table1, Fig. 1).

The results represent that the countable bronchi in VD radiographs were markedly lesser than lateral projection in both techniques (Table 1, Fig. 1).

The number of measureable bronchial lung pattern was significantly different between the 1st and 2nd radiologist in the VD view and but it was significantly compatible in lateral view (Table 1, Fig. 1).

Among different ages, significant difference was only observed in the lateral projections of the analog images interpreted by just one of the radiologists in the 6 years old group which shows higher number of countable bronchi which was more than the

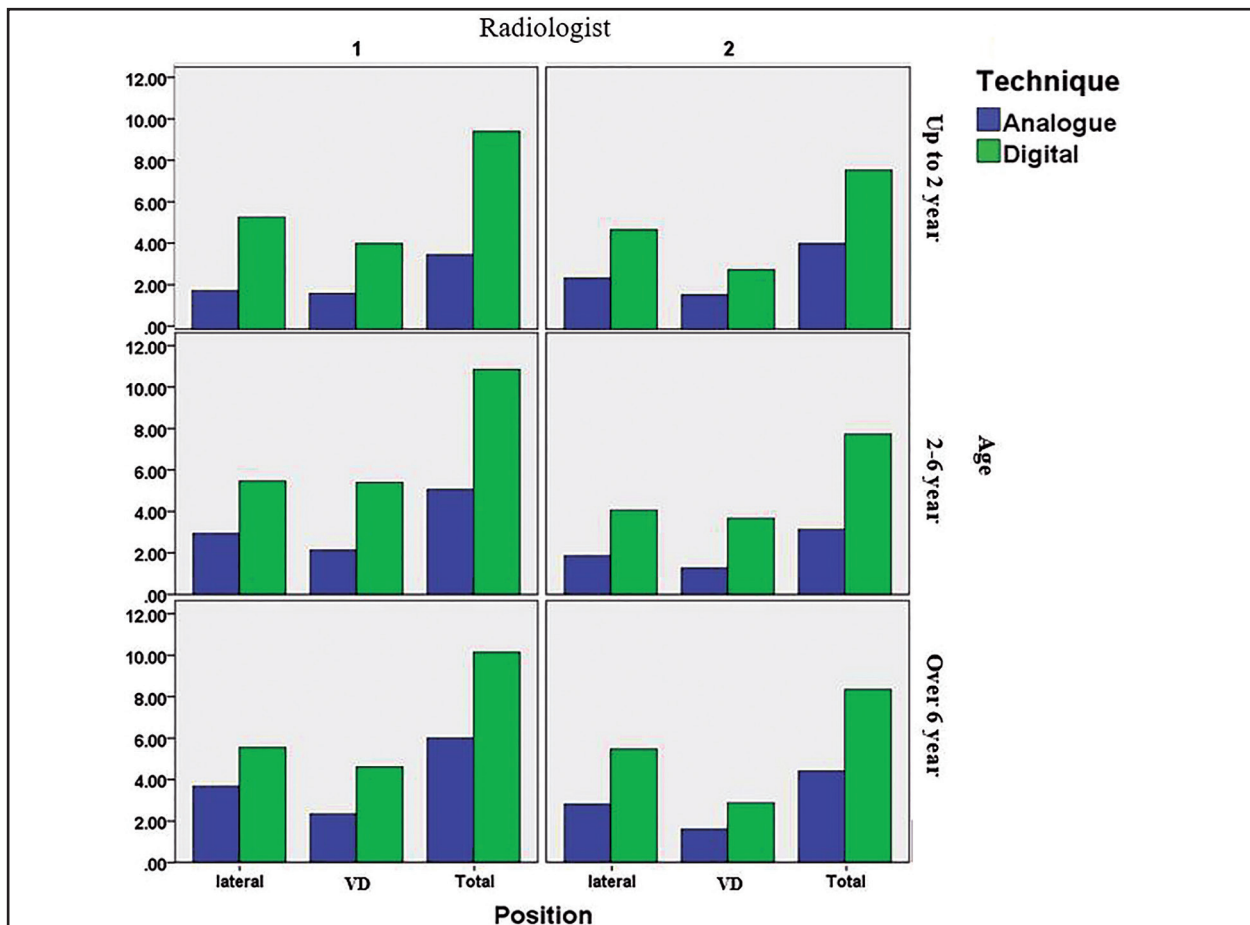


Figure 1. Mean rate of recorded bronchi in both right lateral and ventrodorsal positions through digital and analog radiographs by two radiologists in each age group of dogs.

other age groups (Table 1, Fig.1).

Discussion

Based on the result of this study, two radiologists reported higher rate of countable bronchi through digital radiography compare with analog technique (Fig. 1). Some features such as edge enhancement filters in reconstruction algorithms, Post Processing and Dynamic Range of digital radiography may be of the major differences with analog technique.

In present study, both digital and analog techniques showed dramatically higher rate of countable bronchi in lateral radiography than VD positioning which may be related to increased chance of observation of end on

positing of the bronchi in the lateral view.

Meyer-Lindenger et al (2008) compared six anatomical regions including thorax, abdominal cavity, skull, femur bone, hip and elbow joints in dogs by digital and analog radiography, and demonstrated that digital radiography showed more obvious details than analog technique in all zones.

Rhodes and Reif (1996) and Lord and Suter (1984) claimed that age-dependent pulmonary histopathological alterations, including diffuse increase of interstitium diameter, pleural thickness and mineralized bronchi, can be radiographically diagnosed. Since these findings may be observed in chronic bronchitis and the majority of elderly dogs suffer from such disease as well, precise assessment in radiographic interpre-

tation of such dogs should be considered, therefore, the higher amounts of bronchial pattern detectable in the over 6 years old group by the 1st radiologist can be simply related to age difference.

Scrivani (2009) and Reed (1997) claimed that pulmonary patterns are not appropriate for disease classification, and this kind of classification is no longer used in human medicine as well. Furthermore, macroscopic pictures (radiographs) do not represent microscopic lesions exactly.

On the other hand, increased density of bronchial wall and interstitial bronchovascular play a role in bronchial pattern emergence, the latter of which is not commonly correlated with bronchial wall disorders. Presence of lymphatic and blood vessels of interstitial tissue in the vicinity of bronchi may give rise to bronchial pattern, when pathologically involved. But when respiratory air ways are involved, the bronchi may be filled by fluids which produce radiographs with a density of small and circular soft tissue, representing pulmonary small nodules.

Radiographic diagnosis of pulmonary small nodules referring to metastasis, embolic pneumonia or fungal diseases. Thus, differentiation of fluid filled bronchi is extremely difficult from pulmonary small nodules. Scrivani suggested bronchocentric term rather than of bronchial and believes that bronchocentric refers to macroscopic disorder in bronchovascular zone. He believes that making microscopic differential diagnosis list from affected structures through thoracic radiography is not sufficiently accurate.

Mathieson et al (1989) and Suter and Chan (1968) reported that conventional pulmonary pattern used in radiographic inter-

pretation refers to microscopic distribution of pathogen or complications in alveoli, interstitial tissue, bronchi and pulmonary vessels. But, all radiologists do not have comprehensive agreement on such classification.

Dunworth (1993) stated that the common pulmonary pattern classification needs essential changes, and determining the affected zones as cranioventral, caudodorsal, focal, multifocal and diffuse is considerably advantageous in making a list of differential diagnosis.

Farrow (1995) reported that medical radiologists have rejected this kind of classification because of low precision and less general agreement on diagnosis.

In Alexander et al's (2012) study which was a comparison of computed tomography (CT), digital and analog radiography for detection of canine pulmonary nodules, larger number of smaller pulmonary nodules was detected with CT, and CT allowed greater diagnostic confidence as to the presence or absence of pulmonary nodules. In addition, excellent interobserver diagnostic accuracy and agreement were seen with CT. Nisterok et al (2013) believed that in general, radiography still plays an important role as a screening method for the detection of nodular lung lesions but plane radiographs are of poor diagnostic value when concurrent problems exist which lead to increased lung opacity. They also showed that nodules were better defined and more smoothly marginated on CT.

This study has a few limitations including, lack of knowledge about exact background clinical history of the cases because they had been gathered from a shelter or were homeless dogs. The other limitation was absence of CT, histology or pathology of the lungs

parenchyma. However, all the selected dogs had been clinically and paraclinically healthy and without any respiratory abnormality. Moreover, all dogs underwent radiologic exam by using the same X-ray unit, for digital and analog system which can be a positive factor for stable study condition but a limitation for comparing the results with other machines and modalities.

We recommend to continue this study by comparing these findings with other different radiology systems and also abnormal lung parenchyma in different breed specific dog groups, confirming the results using CT.

According to extensive application of digital radiography in veterinary medicine and present study results, more recorded countable bronchi through digital radiography than analog radiography should not necessarily make radiologists diagnose respiratory air way disorders. Since digital radiography is used more commonly by veterinary practitioners it is necessary to understand the shortcomings of current classification of pulmonary pattern approach.

Acknowledgments

This study was supported by Department of Surgery and Radiology from the Faculty of Veterinary Medicine, University of Tehran. The authors thank Dr. Fardin Barati, Dr. Morteza Ezzati and Alireza Ghovati for their assistance and for performing the clinical and paraclinical tests used in this study.

References

- Alexander, K., Joly, H., Blond, L., D'Anjou, M. A., Nadeau, M. È., Olive, J., Beauchamp, G. (2012) A comparison of computed tomography, computed radiography, and film-screen radiography for the detection of canine pulmonary nodules. *Vet Radiol Ultrasound*. 53: 258-265.
- Donald E. Thrall (a) (2013) Principles of radiographic interpretation of the Thorax, In Thrall, *Textbook of Veterinary Diagnostic Radiology*. 6TH ed. Saunders Company, Philadelphia. U.S.A. p. 474-488.
- Donald E. Thrall (b) (2013) The Canine and Feline Lung, In Thrall, *Textbook of Veterinary Diagnostic Radiology*. 6TH ed. Saunders Company, Philadelphia. U.S.A. p. 608-631.
- Drost, W. T. (2011) Transitioning to digital radiography. *J Vet Emerg Crit Care*. 21: 137-143.
- DuNWorth, D. (1993) The respiratory system. In: *Pathology of Domestic Animals*. Jubb, K.V.F., Kennedy, P.C., Palmer, N., (eds.) Academic Press, San Diego, USA. p. 538-699.
- Farrow, C. S. (1995) Critical thinking: the perils of pattern recognition. *Can Vet J*. 36: 57-58.
- Ganten, M., Radeleff, B., Kampschulte, A., Daniels, M.D., Kauffmann, G.W., Hansmann, J. (2003) Comparing image quality of flat-panel chest radiography with storage phosphor radiography and film-screen radiography. *AJR Am J Roentgenol*. 181: 171-176.
- Konen, E., Greenberg, I., Rozenman, J. (2005) Visibility of normal thoracic anatomic landmarks on storage phosphor digital radiography versus conventional radiography. *IMAJ*. 7: 495-497.
- Mathieson, J. R., Mayo, J. R., Staples, C. A., Müller, N. L. (1989) Chronic diffuse infiltrative lung disease: comparison of diagnostic accuracy of CT and chest radiography. *Radiology*, 171: 111-116.
- Meyer-Lindenberg, A., Ebermaier, C., Wolvekamp, P., Tellheim, B., Meutstege, F.J., Lang, J., Hartung, K., Fehr, M., Nolte, I. (2008) Comparative evaluation of analog and digital radiographs of six different body-regions of the dog. *Berl Munch Tierarztl J*. 121: 216-

227. (in German).
- Niesterok, C., Köhler, C., Ludewig, E., Alef, M., Oechtering, G., Kiefer, I. (2013) Comparison of projection radiography and computed tomography for the detection of pulmonary nodules in the dog and cat. *Tieraerztl Prax K H.* 41: 155-162. (in German).
- Reed, J.C. (1997) *Chest radiology: plain film patterns and differential diagnoses.* 6TH ed. Elsevier Health Sciences, Philadelphia. U.S.A. p. 185-432.
- Reeder M., Felson B. (2003) *Reeder and Felson's Gamuts in Radiology: Comprehensive Lists of Roentgen Differential Diagnosis.* 4th ed. Springer-Verlag, New York. U.S.A. p, 493-530.
- Reif, J.S., Rhodes, W.H. (1966) The Lungs of Aged Dogs: A Radiographic-Morphologic Correlation. *Vet Radiol Ultrasound.* 7: 5-11.
- Scrivani, P.V. (2009) Nontraditional interpretation of lung patterns. *Veterinary Clinics of North America: J Small Anim Pract.* 39: 719-732.
- Suter, P. F., Chan, K. F. (1968) Disseminated Pulmonary Diseases in Small Animals: A Radiographic Approach to Diagnosis. *Vet Radiol Ultrasound.* 9: 67-79.
- Suter, P.F., Lord, P.F. (1984) *Thoracic Radiography: A Text Atlas of Thoracic Diseases of the Dog and Cat.* Peter, F. (ed.). Suter. Wettswil, Switzerland. p. 1-45.

