

## Oxaliplatin Treatment for 3-Weeks Does not Affect Mice Kidney Structure: A Stereological Study

Javad Sadeghinezhad<sup>1\*</sup>, Jens R. Nyengaard<sup>2</sup>

1. Department of Basic Sciences, Faculty of Veterinary Medicine, University of Tehran, Tehran, Iran
2. Core Centre for Molecular Morphology, Section for Stereology and Microscopy, Centre for Stochastic Geometry and Advanced Bioimaging, Aarhus University, Aarhus, Denmark

### Abstract

**BACKGROUND:** Oxaliplatin (OX) is the third-generation platinum anticancer drug used to treat various types of cancers. Although oxaliplatin has a renal metabolism, the evaluation of its nephrotoxicity is limited.

**OBJECTIVES:** This study describes the morphometry of mouse kidneys using stereology following OX treatment.

**METHODS:** Twenty Balb/C healthy male adult mice were divided into two groups. The mice from group 1 received 3 mg/kg oxaliplatin three times a week for 21 days, and in group 2 the mice were injected with saline. The left kidneys were used to measure the kidney volume, the volume fraction of cortex and medulla, glomerular volume, glomerular mean volume, glomerular number, epithelial volume, and length of the proximal (PCT) and distal (DCT) convoluted tubules.

**RESULTS:** No significant differences in total kidney volume, the volume of cortex, and medulla were observed between control and experimental animals ( $P \geq 0.05$ ). No differences were observed in either epithelial volume of PCT and DCT or total length of PCT and DCT between the control and experimental group ( $P \geq 0.05$ ). The glomerular volume fraction, total glomerular volume, mean glomerular volume, and glomerular number did not differ between control and the treated animals ( $P \geq 0.05$ ).

**CONCLUSIONS:** The results did not demonstrate any deleterious effect of OX in the mentioned dose on kidney structure in mice. These findings may help infer contradictory outcomes of different studies in this field and promote future investigations.

**KEYWORDS:** Kidney, Mice, Oxaliplatin, Stereology

### Correspondence

Javad Sadeghinezhad, Department of Basic Sciences, Faculty of Veterinary Medicine, University of Tehran, Tehran, Iran. Tel: +98 (021) 61117116, Fax: +98 (021) 66933222, Email: [Sadeghinezhad@ut.ac.ir](mailto:Sadeghinezhad@ut.ac.ir)

Received: 2021-09-14

Accepted: 2021-12-07

Copyright © 2022. This is an open-access article distributed under the terms of the Creative Commons Attribution- 4.0 International License which permits Share, copy and redistribution of the material in any medium or format or adapt, remix, transform, and build upon the material for any purpose, even commercially.

#### How to Cite This Article

Sadeghinezhad, J, Nyengaard, J R. (2022). Oxaliplatin Treatment for 3-Weeks Does not Affect Mice Kidney Structure: A Stereological Study. *Iranian Journal of Veterinary Medicine*, 16(2), 101-109.

## Introduction

Oxaliplatin is the third-generation platinum anti-cancer drug with the 1, 2- diaminocyclohexane in place of the amine group and oxalate in the active group (Kanou *et al.*, 2004). It forms DNA intra-strand crosslinks which inhibit DNA replication, transcription, and ultimately cell division, causing apoptosis or necrosis in cancer cells (Wafai *et al.*, 2013). Oxaliplatin is commonly used to treat metastatic colorectal cancer (Petrioli *et al.*, 2008). It is also active against advanced cancers, which are resistant to first-generation (cisplatin) and second-generation (carboplatin) platinum drugs (Wafai *et al.*, 2013). Therefore, oxaliplatin has been administered to treat various types of cancers such as gastric, pancreatic, ovarian, breast, and lung cancers (Misset *et al.*, 2000).

The most common side effects of this drug are neuropathy, nausea, vomiting, and hematologic toxicity (Márquez *et al.*, 2013; Jain *et al.*, 2015). Oxaliplatin is associated with less nephrotoxicity relative to other platinum derivatives like cisplatin, which is dose-limited due to renal toxicity (Márquez *et al.*, 2013). Although oxaliplatin has a renal metabolism, the evaluation of its nephrotoxicity in preclinical studies is limited (Mathé *et al.*, 1985; Cambar and Pourquier, 1990; Legallicier *et al.*, 1996). It showed a similar nephrotoxic pattern to cisplatin in an *in vitro* study using renal cortical-slices, whereas it did not cause nephrotoxicity in an *in vivo* study (Kanou *et al.*, 2004). However, some case reports have indicated various renal toxicity forms due to oxaliplatin administration (Márquez *et al.*, 2013; Filewod and Lipman, 2014; Joybari *et al.*, 2014; Jain *et al.*, 2015; Choi *et al.*, 2018).

In the present study, stereology was used to estimate the volume of kidney, cortex, medulla, and glomeruli, estimate the glomerular number as well as epithelial volume and length of the proximal and distal convoluted tubules (PCT and DCT, respectively) in mouse treated with oxaliplatin for better evaluation of its nephrotoxicity.

## Materials and Methods

### Animal Experiments

Twenty Balb/C healthy male adult mice (Pasteur Institute, Tehran, Iran) aged 8 weeks ( $25 \pm 1.5$  g) were kept on a 12 h light and dark cycle at  $22 \pm 2^\circ\text{C}$  with *ad libitum* food and water. The mice from group 1 received 3 mg/kg oxaliplatin (Intas Pharmaceuticals Ltd., India) three times a week for 21 days. In group 2, mice were injected intraperitoneally with normal saline (Misset *et al.*, 2000). Mice were euthanized by cervical dislocation at the end of the experimental period.

### Tissue Sampling and Stereological Methods

The left kidneys were dissected and were weighed using a digital scale. Isotropic, uniformly random (IUR) designs were applied for sampling each kidney (Nyengaard, 1999). Kidneys were embedded in agar, and the orientator method was performed (Figure 1). In the first step, each kidney was placed at the circle's center divided into equal parts. A random number between 0 and 99 was selected, and the embedding media was cut in that direction. In the second step, the kidney halves were placed on the cut agar surface on the second circle with sine-weighted divisions in the direction 1-1, and a random number between 0 and 99 was chosen. Afterward, kidney halves were sectioned into 2 mm thickness slabs parallel to the direction of the selected random number.

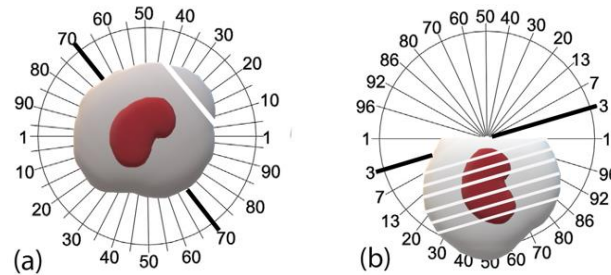
### Estimation of the Volume

The volume of the kidney was estimated using its weight. The volume density and total volume of the renal cortex, medulla, glomeruli, PCT, and DCT epithelium were estimated by a point-counting method (Figure 2a) and the following formula on thin sections (Gundersen *et al.*, 1988):

$$V_v(\text{structure/kidney}) = \frac{P(\text{structure})}{P(\text{kidney})}$$

$$V(\text{structure}) = V_v(\text{structure}) \cdot V(\text{kidney})$$

where  $P(\text{structure})$  and  $P(\text{kidney})$  are the total number of the points hitting the structure (cortex, medulla, glomeruli, PCT, and DCT epithelium) and the kidney, respectively.



**Figure 1.** Schematic diagram of the orientator method to generate isotropic, uniformly random (IUR) sections. (a): kidney was placed at the center of the circle divided into equal parts. A random number between 0 and 99 was selected (here 70), and the embedding media was cut in that direction. (b): kidney halves were placed on the cut agar surface on the second circle with sine-weighted divisions, and a random number between 0 and 99 was selected (here 3). Afterward, kidney halves were sectioned into 2-mm-thick slabs parallel to the direction of the selected random number.


**Estimation of Length of Renal Tubules**

The length density and total length of the PCT and DCT were estimated by using an unbiased counting frame (Figure 2b) and the following formula on thin IUR sections (Nyengaard, 1999):

$$L_v (\text{tubules} / \text{kidney}) = \frac{2 \cdot \sum Q}{a(\text{frame}) \cdot \sum P(\text{kidney})}$$

$$L (\text{tubules}) = L_v (\text{tubules}) \cdot V (\text{kidney})$$

Where  $\sum Q$  (tubules) is the total number of PCT or DCT profiles which is in the counting frame and does not touch the exclusion lines of the frame;  $a$  (frame) is the area per frame;  $P$  (kidney) is the total number of test points hitting the kidney.



**Figure 2.** Stereological procedure for estimation of volume and length of kidney structures. (a): The point counting grid was superimposed on the kidney section to estimate volume structure. The right upper corner of each test point (see arrow) was considered for hitting relevant renal structures (periodic acid Schiff staining technique, scale bar 250  $\mu\text{m}$ ). (b): The counting frame with exclusion lines (red) and inclusion lines (green) was superimposed on the kidney section for length estimation. The profiles of tubules that were either entirely or partly inside the counting frame and did not touch the exclusion lines (red lines) were counted. Note that the larger frame was used for counting proximal convoluted tubules, while the smaller one was used for distal convoluted tubules. Here three proximal (PCT) and two distal (DCT) convoluted tubule profiles are counted (periodic acid Schiff staining technique, scale bar 100  $\mu\text{m}$ ).

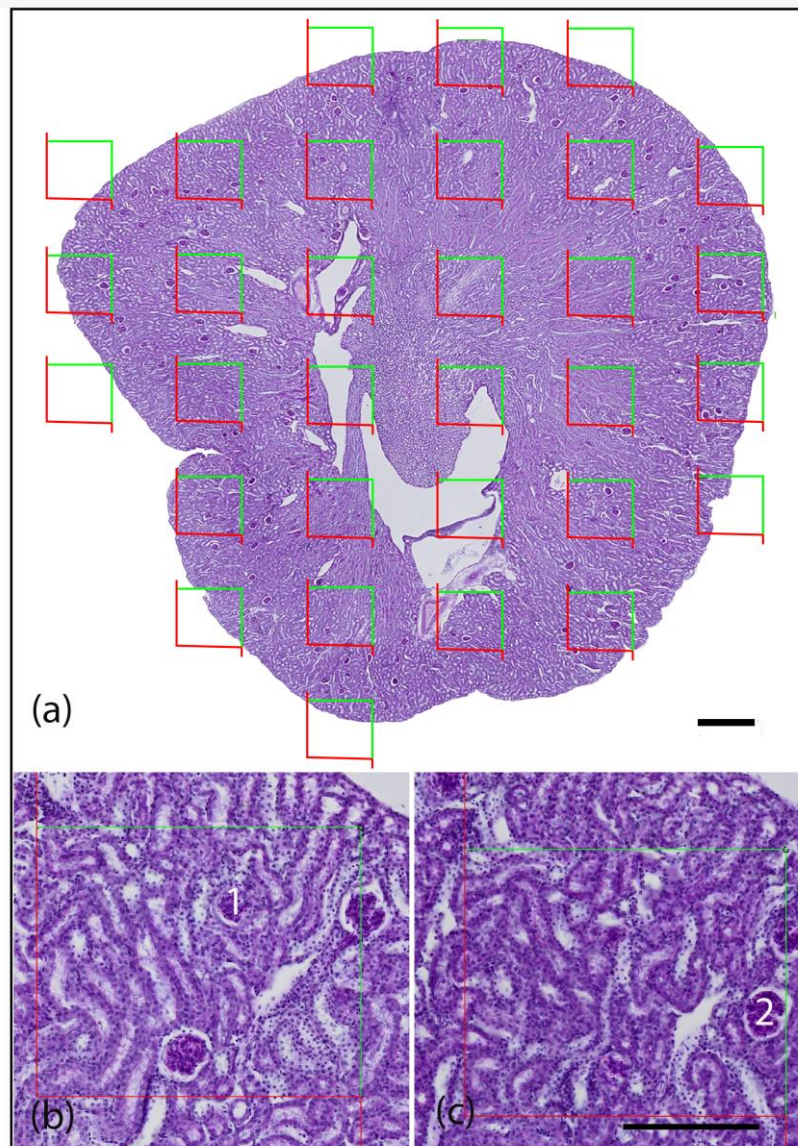
**Estimation of the Number of Glomeruli**

The physical fractionator method was applied for counting glomeruli on thick section disector pairs (sampling and look-up sections). An unbiased counting frame was superimposed on a known fraction of the two slides by moving the motorized microscope stage in equidistant steps in x- and y-directions. The glomerular were sampled in the reference sections, and then glomeruli which were not seen in the look-up sections, were counted (Figure 3). Reference and

look-up sections were reversed to double the number of disector pairs. The total number of glomeruli in each kidney was calculated as the sum of counted glomeruli multiplied with the total inverse fractions (Lødrup *et al.*, 2008):

$$N (\text{glom}) = \frac{1}{BSF} \cdot \frac{1}{ASF} \cdot \frac{\sum Q (\text{glom})}{2}$$

where  $\sum Q$  is the number of counted glomeruli, ASF is the area sampling fraction, and BSF is the block sampling fraction.



**Figure 3.** Estimation of the number of glomeruli using the physical fractionator method. (a): A known areal fraction of the two sections were sampled using the motorized microscope stage with an equal step length in the x- and y-directions (periodic acid Schiff staining technique, scale bar 500  $\mu\text{m}$ ). (b): reference section and (c): look-up section. An unbiased counting frame was superimposed on each field of view. Then, glomerular profiles inside the counting frame or touching the inclusion lines (green) without touching the exclusion lines (red) were sampled by the counting frame in the reference section. Glomeruli were counted if present in the reference section but not present in the look-up section (glomerular profile 1 here). Reference and look-up sections were reversed to increase the efficiency of the technique. In this way, another glomerulus (2) was counted (periodic acid Schiff staining technique, scale bar 250  $\mu\text{m}$ ).

### Estimation of Mean Volume of Glomerulus

The number-weighted mean glomerular volume was calculated using the following formula (Kellenberger *et al.*, 2013):

$$V_n = \frac{V(\text{glomeruli})}{N(\text{glomeruli})}$$

where V (glomeruli) is the total volume of glomeruli and N (glomeruli) is the total number of glomeruli in the kidney.

### Statistical Analysis

The results were expressed as mean  $\pm$  standard deviation. Student t-test was applied for comparison mean between groups. A P-value  $< 0.05$  was considered statistically significant.

**Results**

No impairments of oxaliplatin (3 mg/kg three times a week for 21 days) treatment on kidney structure could be observed in this study using design-unbiased stereology.

The results for the kidney volume and its two main compartments are summarized in [Table 1](#). No significant differences in total kidney volume (297±46 mm<sup>3</sup> vs 293±36 mm<sup>3</sup>), volume of cortex (184±34 vs 204 ±33 mm<sup>3</sup>) and medulla (107±37.2 mm<sup>3</sup> vs 89.1±14.5 mm<sup>3</sup>) were observed between control and experimental animals ( $P \geq 0.05$ ).

The stereological data for PCT and DCT are illustrated in [Table 2](#). No differences were observed in

either epithelial volume of PCT (11.7 ±4.5 cm<sup>3</sup> vs. 11±3.9 cm<sup>3</sup>) and DCT (3.15±0.98 cm<sup>3</sup> vs. 3.02±1.12 cm<sup>3</sup>) or total length of PCT (103 ± 43 m vs. 93.1 ± 34.5 m) and DCT (29.7± 14.1 m vs. 20.4± 6.1 m) between control and experimental groups ( $P \geq 0.05$ ).

The results for the glomerular volume and number are shown in [Table 3](#). The glomerular volume fraction (1.32 ± 0.48% vs. 1.55±0.26%), total glomerular volume (3.8 ± 1.1 mm<sup>3</sup> vs. 4.5 ± 0.8 mm<sup>3</sup>), mean glomerular volume (0.41 ± 0.2 · 10<sup>6</sup> μm<sup>3</sup> vs. 0.53 ± 0.29 · 10<sup>6</sup> μm<sup>3</sup>) and glomerular number (10274 ± 3057 vs. 9402 ± 3677) did not differ between control and the treated animals ( $P \geq 0.05$ )

**Table 1.** Total volume of kidney and fractional and total volume of cortex and medulla of the control and experimental groups.

Groups	Kidney volume (mm <sup>3</sup> ) using specific kidney tissue density	Kidney volume (mm <sup>3</sup> ) using Cavalieri 's method	Cortex volume fraction (%)	Cortex volume (mm <sup>3</sup> )	Medulla volume fraction (%)	Medulla volume (mm <sup>3</sup> )
Control	297±46	231±72	62±7	184±34	37.8±7	<b>107±37.2</b>
Experimental	293±36	206±59	69.3±5	204±33	30.5±5	<b>89.1±14.5</b>

The data are expressed as mean ± SD values

**Table 2.** Epithelial volume and total length of proximal (PCT) and distal (DCT) convoluted tubules of the control and experimental groups.

Groups	PCT epithelial volume (cm <sup>3</sup> )	DCT epithelial volume (cm <sup>3</sup> )	PCT length (m)	DCT length (m)
Control	11.7±4.5	3.15± 0.98	103±43	<b>29.7±14.1</b>
Experimental	11±3.9	3.02±1.12	93.1±34.5	<b>20.4±6.1</b>

**Table 3.** Glomerular volume fraction, total glomerular volume, mean glomerular volume, and the glomerular number of the control and experimental groups.

Groups	Glomerular volume fraction (%)	Total glomerular volume (mm <sup>3</sup> )	Mean glomerular volume (10 <sup>6</sup> . μm <sup>3</sup> )	Glomerular number
Control	1.32±0.48	3.8±1.1	0.41±0.2	<b>10274±3057</b>
Experimental	1.55±0.26	4.5±0.8	0.53±0.29	<b>9402±3677</b>

## Discussion

The effect of oxaliplatin on the kidney was examined using stereological methods in this study. The results did not demonstrate any deleterious effect of oxaliplatin on kidney structure.

Indeed, oxaliplatin has been developed as a newer generation of platinum anticancer agents with high water solubility and reduced nephrotoxicity (Ali, 2010). Accordingly, oxaliplatin did not show any renal toxicity in experimental animal studies. Mathé *et al.* have reported neither changes in blood urea nitrogen and serum creatinine nor histopathological damage in mice kidneys after oxaliplatin treatment (Mathé *et al.*, 1985). Cambar and Pourquier have examined urinary creatinine and enzyme excretion and did not report any alteration following oxaliplatin administration in rats (Cambar and Pourquier, 1990).

Based on *in vitro* studies, Legallicier *et al.* have reported a low cytotoxic effect of oxaliplatin in rabbit tubular cells (1996). While, according to Waly *et al.*, oxaliplatin increases cell death and cell membrane damage and induces oxidative stress in human embryonic kidney cells (2011). Similarly, Kanou *et al.* have reported a nephrotoxic effect of oxaliplatin *in vitro* using renal cortical-slices and no nephrotoxicity in an *in vivo* study (2004). They explained that *in vitro* experiments may not directly reflect the *in vivo* renal toxicity. The concentration of active biological oxaliplatin may differ from that under fixed conditions *in vitro*.

Oxaliplatin did not show any nephrotoxicity in clinical trials, and it was selected for clinical development based on its favorable activity/toxicity profile (Extra *et al.*, 1990; Taguchi *et al.*, 1998; Masari *et al.*, 2000; Takimoto *et al.*, 2007). However, recent case reports suggest induction of renal toxicity like acute tubular necrosis (Filewod and Lipman, 2014; Pinotti and Martinelli, 2002), renal tubular acidosis (Linch *et al.*, 2007; Negro *et al.*, 2010), hemolytic anemia (Phull *et al.*, 2016) in patients by oxaliplatin in combination with other agents. Generally, oxaliplatin may induce renal toxicity through direct renal effect as a result of renal accumulation (Joybari *et al.*, 2014) or immune-mediated renal damage due to oxaliplatin-dependent anti-red blood

cell antibodies (Cobo *et al.*, 2007; Forcello *et al.*, 2015). Some studies revealed that imbalance between organic cation transporters in the basolateral membrane and multidrug and toxin extrusion transport proteins in the brush border membrane of PCT can cause platinum renal accumulation and nephrotoxicity (Yokoo *et al.*, 2007; Yonezawa and Inui, 2010). However, the exact cellular and molecular mechanism of oxaliplatin effect on the kidney is not clear. Our animal experimental study which examined the epithelial volume and length of PCT and also DCT along with cortex volume (which is mainly formed by PCT and DCT) did not show any change in oxaliplatin treated animals. However, it is presumed that repeated cycles of oxaliplatin treatment in patients and association with 5-fluorouracil can cause nephrotoxicity (Márquez *et al.*, 2013; Jain *et al.*, 2015; Waly *et al.*, 2011).

It has been shown that oxaliplatin binds to plasma protein and is excreted into the urine; however, it is unclear whether it has a glomerular filtration or renal tubular secretion for the detailed assessment of kidney injury (Kanou *et al.*, 2004). In this study, glomerular quantities (glomerular mean volume, total glomerular volume, and glomerular number) were investigated and did not demonstrate any change following oxaliplatin treatment in mice.

## Conclusion

In conclusion, oxaliplatin administration (3 mg/kg) for 3-weeks did not show an adverse effect on the kidney. These findings may help infer contradictory outcomes of different studies in this field and offer a baseline for future detailed studies with varying doses of oxaliplatin treatment.

## Acknowledgments

None.

## Conflict of Interest

The authors have nothing to disclose.

## References

- Ali, BH. (2010). Amelioration of oxaliplatin neurotoxicity by drugs in humans and experimental animals: a mini-review of recent literature. *Basic & Clinical Pharmacology & Toxicology*, 106(4), 272-279. [DOI:10.1111/j.1742-7843.2009.00512.x] [PMID]
- Cambar, J., Pourquier, K. (1990). Comparison of the nephrotoxicity of three platinum derivatives: an in vivo experimental approach, internal report. Bordeaux: Bordeaux II University.
- Choi, YJ., Oh, KH., Kang, HR., Lee, SJ. (2018). Oxaliplatin-induced acute tubulointerstitial nephritis: Two case reports. *Clinical Nephrology*, 89(2), 130. [DOI:10.5414/CN109131] [PMID]
- Cobo, F., De Celis, G., Pereira, A., Latorre, X., Pujadas, J., Albiol, S. (2007). Oxaliplatin-induced immune hemolytic anemia: a case report and review of the literature. *Anticancer Drugs*, 18(8), 973-976. [DOI:10.1097/CAD.0b013e3280e9496d] [PMID]
- Extra, JM., Espie, M., Calvo, F., Ferme, C., Mignot, L., Marty, M. (1990). Phase I study of oxaliplatin in patients with advanced cancer. *Cancer Chemotherapy and Pharmacology*, 25(4), 299-303. [DOI:10.1007/BF00684890] [PMID]
- Filewod, N., Lipman, ML. (2014). Severe acute tubular necrosis observed subsequent to oxaliplatin administration. *Clinical Kidney Journal*, 7(1), 68-70. [DOI:10.1093/ckj/sft148] [PMID] [PMCID]
- Forcello, NP., Khubchandani, S., Patel, SJ., Brahaj, D. (2015). Oxaliplatin-induced immune-mediated cytopenias: a case report and literature review. *Journal of Oncology Pharmacy Practice*, 21(2), 148-156. [DOI:10.1177/1078155213520262] [PMID]
- Gundersen, H. J. G., Bendtsen, T. F., Korbo, L., Marcussen, N., Møller, A., Nielsen, K., ... & West, M. J. (1988). Some new, simple and efficient stereological methods and their use in pathological research and diagnosis. *Apmis*, 96(1-6), 379-394. [DOI:10.1111/j.1699-0463.1988.tb05320.x] [PMID]
- Jain, A., Dubashi, B., Parameswaran, S., Ganesh, RN. (2015). Oxaliplatin induced acute tubular necrosis. *Indian Journal of Cancer*, 52(3), 363-364. [DOI:10.4103/0019-509X.176696] [PMID]
- Yaghobi Joybari, A., Sarbaz, S., Azadeh, P., Mirafsharieh, S. A., Rahbari, A., Farasatinasab, M., & Mokhtari, M. (2014). Oxaliplatin-induced renal tubular vacuolization. *The Annals of Pharmacotherapy*, 48(6), 796-800. [DOI:10.1177/1060028014526160] [PMID]
- Kanou, T., Uozumi, J., Soejima, K., Tokuda, Y., Masaki, Z. (2004). Experimental study of renal disorder caused by oxaliplatin in rat renal cortical slices. *Clinical and Experimental Nephrology*, 8, 310-315. [DOI:10.1007/s10157-004-0304-0] [PMID]
- Kellenberger, T., Krag, S., Danielsen, C. C., Wang, X. F., Nyengaard, J. R., Pedersen, L., ... & Wogensen, L. (2013). Differential effects of Smad3 targeting in a murine model of chronic kidney disease. *Physiological Reports*, 1(7), e00181. [DOI:10.1002/phy2.181] [PMID] [PMCID]
- Legallicier, B., Leclere, C., Monteil, C., Elkaz, V., Morin, JP., Fillastre, JP. (1996). The cellular toxicity of two antitumoral agents derived from platinum, cisplatin versus oxaliplatin, on cultures of tubular proximal cells. *Drugs under Experimental and Clinical Research*, 22(2), 41-50.
- Linch, M., Cunningham, D., Mingo, O., Stiles, A., Farquhar-Smith, WP. (2007). Renal tubular acidosis due to oxaliplatin. *The Annals of Oncology*, 18(4), 805-806. [DOI:10.1093/annonc/mdm080] [PMID]
- Lødrup, AB., Karstoft, K., Dissing, TH., Nyengaard, JR., Pedersen, M. (2008). The association between renal function and structural parameters: a pig study. *BMC Nephrology*, 9(1), 1-9. [DOI:10.1186/1471-2369-9-18] [PMID] [PMCID]
- Márquez, E., Rodríguez, E., Pascual, J. (2013). Inadvertent severe acute kidney injury and oxaliplatin. *International Urology and Nephrology*, 45(1), 297. [DOI:10.1007/s11255-012-0177-1] [PMID]
- Massari, C., Brienza, S., Rotarski, M., Gastiburu, J., Misset, J. L., Cupissol, D., ... & Bastian, G. (2000). Pharmacokinetics of oxaliplatin in patients with normal versus impaired renal function. *Cancer Chemotherapy and Pharmacology*, 45(2), 157-164. [DOI:10.1007/s002800050024] [PMID]
- Mathe, G., Kidani, Y., Noji, M., Maral, R., Bourut, C., & Chenu, E. (1985). Antitumor activity of l-OHP in mice. *Cancer Letters*, 27(2), 135-143. [DOI:10.1016/0304-3835(85)90102-8]

- Misset, J.L., Bleiberg, H., Sutherland, W., Bekradda, M., Cvitkovic, E. (2000). Oxaliplatin clinical activity: a review. *Critical Reviews in Oncology/Hematology*, 35(2), 75-93. [DOI:10.1016/S1040-8428(00)00070-6]
- Negro, A., Grasselli, C., Galli, P. (2010). Oxaliplatin-induced proximal renal tubular acidosis. *Internal and Emergency Medicine*, 5(3), 267-268. [DOI:10.1007/s11739-009-0331-7] [PMID]
- Nyengaard, JR. (1999). Stereologic methods and their application in kidney research. *J Am Soc Nephrol*, 10(5), 1100-1123. [DOI:10.1681/ASN.V1051100] [PMID]
- Petrioli, R., Pascucci, A., Francini, E., Marsili, S., Sciandivasci, A., Tassi, R., ... & Francini, G. (2008). Neurotoxicity of FOLFOX-4 as adjuvant treatment for patients with colon and gastric cancer: a randomized study of two different schedules of oxaliplatin. *Cancer Chemotherapy and Pharmacology*, 61(1), 105-111. [DOI:10.1007/s00280-007-0454-3] [PMID]
- Phull, P., Quillen, K., Hartshorn, KL. (2016). Acute oxaliplatin-induced hemolytic anemia, thrombocytopenia, and renal failure: Case report and a literature review. *Clinical Colorectal Cancer*, S1533-0028(16), 30259-30256. [DOI:10.1016/j.clcc.2016.11.005] [PMID]
- Pinotti, G and Martinelli, B (2002). A case of acute tubular necrosis due to oxaliplatin. *The Annals of Oncology*, 13(12), 1951-1952. [DOI:10.1093/annonc/mdf311] [PMID]
- Taguchi, T., Tsukagoshi, S., Furue, H., Niitani, H., & Noda, K. (1998). Phase I clinical study of oxaliplatin. *Gan to kagaku ryoho. Cancer Chemotherapy*, 25(12), 1899-1907.
- Takimoto, C. H., Graham, M. A., Lockwood, G., Ng, C. M., Goetz, A., Greenslade, D., ... & Grem, J. L. (2007). Oxaliplatin pharmacokinetics and pharmacodynamics in adult cancer patients with impaired renal function. *Clinical Cancer Research* 13(16), 4832-4839. [DOI:10.1158/1078-0432.CCR-07-0475] [PMID]
- Wafai, L., Taher, M., Jovanovska, V., Bornstein, J. C., Dass, C. R., & Nurgali, K. (2013). Effects of oxaliplatin on mouse myenteric neurons and colonic motility. *Frontiers in Neuroscience*, 7, 30.. [DOI:10.3389/fnins.2013.00030] [PMID] [PMCID]
- Waly, MI., Al Moundhri, MS., Ali, BH. (2011). Effect of curcumin on cisplatin- and oxaliplatin-induced oxidative stress in human embryonic kidney (HEK) 293 cells. *Renal Failure*, 33(5), 518-523. [DOI:10.3109/0886022X.2011.577546] [PMID]
- Yokoo, S., Yonezawa, A., Masuda, S., Fukatsu, A., Katsura, T., Inui, K. (2007). Differential contribution of organic cation transporters, OCT2 and MATE1, in platinum agent-induced nephrotoxicity. *Biochemical Pharmacology*, 74(3), 477-487. [DOI:10.1016/j.bcp.2007.03.004] [PMID]
- Yonezawa, A., Inui, K. (2010) Organic cation transporter OCT/SLC22A and H(+)/organic cation antiporter MATE/SLC47A are key molecules for nephrotoxicity of platinum agents. *Biochemical Pharmacology*, 81(5), 563-568. [DOI:10.1016/j.bcp.2010.11.016] [PMID].



## درمان با اگزالی پلاتین برای سه هفته برساختار کلیه موش سوری تاثیر ندارد: مطالعه استریولوژی

جواد صادقی نژاد<sup>۱\*</sup>، جنس راندل نینگارد<sup>۲</sup><sup>۱</sup> گروه علوم پایه، دانشکده دامپزشکی، دانشگاه تهران، تهران، ایران<sup>۲</sup> مرکز مورفولوژی مولکولی، بخش اسنریولوژی و میکروسکوپ، مرکز جنومتری سه بعدی و تصویربرداری زیستی پیشرفته، دانشگاه آرهوس، آرهوس، دانمارک

(دریافت مقاله: ۲۳ شهریور ماه ۱۴۰۰، پذیرش نهایی: ۱۶ دی ۱۴۰۰)

**زمینه مطالعه:** اگزالی پلاتین داروی نسل سوم ضدسرطان پلاتینی است که برای درمان انواع مختلف سرطان‌ها مورد استفاده قرار می‌گیرد. با وجود اینکه اگزالی پلاتین متابولیسم کلیوی دارد اما بررسی سمیت کلیوی آن محدود صورت گرفته است.

**هدف:** این مطالعه خصوصیات مورفومتری ساختارهای کلیه موش سوری را متعاقب تجویز اگزالی پلاتین با استفاده روش‌های استریولوژی توصیف می‌کند. **روش کار:** تعداد ۲۰ سر موش سوری نرسالم بالغ نژاد Balb/C به‌طور تصادفی به دو گروه تقسیم شدند. موش‌های گروه اول، اگزالی پلاتین را سه بار در هفته به میزان ۳ میلی‌گرم به ازای کیلوگرم وزن بدن به مدت ۲۱ روز دریافت کردند و در گروه دوم تزریق سالین نرمال صورت گرفت. کلیه‌های چپ از همه حیوانات جدا شد و تکنیک استریولوژی برای محاسبه حجم کلیه، حجم نسبی کورتکس و مدولا، حجم گلوبول‌ها، حجم متوسط گلوبول‌ها، تعداد گلوبول‌ها، حجم اپی‌تلیوم و طول لوله‌های پیچیده پراگزیمال و دیستال استفاده شد.

**نتایج:** اختلاف معنی‌داری در حجم کل کلیه، حجم کورتکس و مدولا بین گروه‌های کنترل و درمان مشاهده نشد ( $P \geq 0.05$ ). اختلاف معنی‌داری در حجم اپی‌تلیوم و طول لوله‌های پیچیده پراگزیمال و دیستال در گروه‌های کنترل و درمان مشاهده نشد ( $P \geq 0.05$ ). حجم نسبی گلوبول‌ها، حجم کل گلوبول‌ها، میانگین حجم گلوبول‌ها و تعداد گلوبول‌ها بین گروه‌های کنترل و درمان تفاوتی نداشت ( $P \geq 0.05$ ).

**نتیجه‌گیری نهایی:** نتایج هیچ‌گونه تاثیر زیان‌آور اگزالی پلاتین بر روی ساختارهای کلیه موش سوری را نشان نداد. این یافته‌ها ممکن است برای تفسیر یافته‌های متناقض مطالعات مختلف در این حوزه کمک‌کننده باشد و منجر به پیشرفت مطالعات آتی در این رابطه شود.

**واژه‌های کلیدی:** کلیه، موش سوری، اگزالی پلاتین، استریولوژی