

## Original Article

## Incidence of Mange Infestation in Rabbits

Layan Yaseen Khalil<sup>1</sup>, Nadia Hamid Mohammed\*<sup>1</sup>, Nadia Sultan Alhayali<sup>1</sup>

Department of Microbiology, College of Veterinary Medicine, University of Mosul, Mosul, Iraq.



**How to Cite This Article** Khalil, L. Y., Mohammed, N. H., & Alhayali, N. S. (2024). Incidence of Mange Infestation in Rabbits. *Iranian Journal of Veterinary Medicine*, 18(2), 195-202. <http://dx.doi.org/10.32598/ijvm.18.2.1005367>

**doi** <http://dx.doi.org/10.32598/ijvm.18.2.1005367>



## ABSTRACT

**Background:** Farmers raise rabbits in abundance in Iraq. Scabies infestation is one of the most prevalent diseases in rabbits. The current study investigates the rabbits' infestation with scabies that cause severe complications such as itchy alopecia, hyperkeratosis, anorexia, self-trauma, and weight loss. In short, the disease has high morbidity and mortality and creates heavy economic losses for farmers.

**Objectives:** This study was designed to detect mange infestation in rabbits using microscopic examination of skin scraping. This study is the first to investigate mange infestation in rabbits in Mosul City, Iraq.

**Methods:** A total of 130 rabbits were examined, and their skin lesions were scraped.

**Results:** Of 130 rabbits, 56(43.1%) were infested with mange, including *Sarcoptes scabiei* var. *cuniculi* (n=50, 38.5%), *Psoroptes cuniculi* (n=32, 25%), *Notoedres cati* var. *cuniculi* (n=26, 20%), *Demodex cuniculi* (n=12, 9%), and *Cheyletiella* spp. (n=4, 3%), with the high infestation rate for *S. scabiei* var. *cuniculi* and the lowest rate for *Cheyletiella* spp. The significant lesions were hyperkeratosis followed by alopecia, then pruritus on many body areas (head, ears, abdomen, back, legs, tail, and perineal area). The highest infestation rate was found on the abdomen and back, while the lowest was on the tail and perineal area. There are significant differences according to age, while no significant differences between the males and females and among three types of infestation (single, double, and mixed).

**Conclusion:** The rabbits were infested with several species with different percentages. There was no significant difference in infestation rates between males and females, although there was a difference between younger and older animals. Lastly, a significant difference was clear among the three types of infestation, and the double one was the dominant infestation rate with 50%.

**Keywords:** Mange infestation, Rabbits, *Notoedres cati* var. *Cuniculi*, *Sarcoptes scabiei* var. *Cuniculi*, *Psoroptes cuniculi*

### Article info:

Received: 12 Agu 2023

Accepted: 17 Oct 2023

Publish: 01 Apr 2024

### \* Corresponding Author:

Nadia Hamid Mohammed, Assistant Professor:

Address: Department of Microbiology, College of Veterinary Medicine, University of Mosul, Mosul, Iraq.

E-mail: [nadiahamid@uomosul.edu.iq](mailto:nadiahamid@uomosul.edu.iq)

## Introduction

Rabbits are essential animals for farmers who raise them in many countries. Inadequate care and diseases are among the most critical challenges facing rabbit breeding (Asmare et al., 2016; Rodrigues et al., 2022).

Skin diseases are among the most common diseases in rabbits (Kumsa et al., 2012), which cause severe economic losses due to complications such as alopecia, pruritus, inappetence, self-inflicted trauma, ear canker, and death (Abdelaziz et al., 2020). In Egypt, sarcoptic mange in rabbits was considered second after coccidiosis, recording the highest percentage of losses (Seddiq et al., 2013). Veterinary ectoparasites in rabbits are economically important parasites as they cause significant loss of weight, productivity, and wool quality, with exudative pruritic skin inflammation, severe erythema, and crust formation (Altamemy, 2014). *Sarcoptes scabiei* and *Pso- roptes cuniculi*, *Pso- roptes cuniculi* were the most common ectoparasites of rabbits (Nuru et al., 2017). The genus *Demodex* occurs in rabbits' hair follicles, sebaceous glands, or epidermal pits (Abu Hafsa et al., 2021). *Noto- edres cati* var. *cuniculi* infestation in rabbits is clinically manifested by the formation of scales and scabs of lips, nose, face, external ear canal, and other body parts (Rao et al., 2020). *Cheyletiella* spp. are large mites burrowing the keratin layer of the skin in humans and domestic animals, resulting in scales with pseudo-tunnels and debris on the skin surface (Cardells et al., 2021). Mange causes many losses, leading to morbidity and mortality rates. In Spain, the epidemic rate has reached 81% of the wild population (León-Vizcaíno, 1999). Due to the lack of studies on scabies in rabbits in Iraq, and given its importance in veterinary and health problems, we decided to investigate the mange infestation of rabbits.

## Materials and Methods

### Study animals

A total of 130 rabbits (56 males and 74 females) were examined for lesions on different parts of the body such as the head, nose, ear canal and pinnae, lips, neck, breast, brisket, legs, feet, back, and genitalia (Taylor et al., 2016).

### Skin scraping

Skin scrapings were taken from rabbits with some clinical signs of mange following the method described by some researchers (Solikhah et al., 2021; Ola-Fadunsin et al., 2023). The skin-scraping samples were transferred to the laboratory of parasitic diseases at the College of Vet-

erinary Medicine at University of Mosul. We followed all instructions and methods of animal welfare laws in accordance with the guidelines of the International Animal Ethics Committee or the Institutional Ethics Committee, as well as the local laws and regulations.

### Laboratory tests

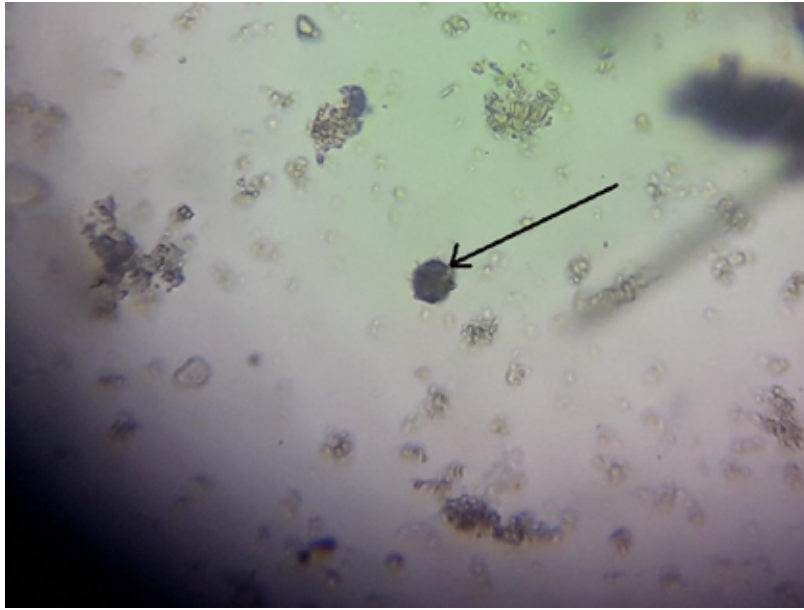
The scraped parts were placed in tubes containing 5 mL of KOH 10%; the tubes were placed in a water bath at 60-80°C for 15 minutes and centrifuged at a speed of 1500-2000 rpm for 5 min, then the supernatant was discarded, and some drops of sediment were placed on a glass slide with cover slide (Yasine et al., 2015). The scabies species were diagnosed based on morphological characteristics using the identification keys (Taylor et al., 2016). Data were analyzed by SPSS software, version 17 (SPSS Inc., Chicago, USA) using the chi-square test.

## Results

In this study, of 130 examined rabbits, 56(43.1%) were naturally infected with several types of mange. The results revealed that *S. scabiei* var. *cuniculi* infected 50 (38.5%), *Pso- roptes cuniculi* 32(25%), *N. cati* var. *cuniculi* 26(20%), *D. cuniculi* 12(9%), and *Cheyletiella* spp. 4(3%) (Table 1 and Figures 1, 2 and 3). Regarding the organ susceptibility to mange infestation, the results showed that the highest infestation was seen in the abdomen and back, while the lowest infestation rate was found on the tail and perineal area. The infestation rate, the typical lesions of symptomatic rabbits, and the sites of those lesions are listed in Table 2. The highest rate of infested sites (alopecia, pruritus, and hyperkeratosis) was found on the abdomen and back, while the lowest lesion rate (alopecia) was found on the tail and perineal area (Figure 4). Based on animal age, the percentage of infestation in the group of animals under one year was 63.3%, while 25% in animals more than one year old. The chi-square test showed a significant difference ( $P \leq 0.05$ ) in the percentage of infestation in relation to the animal age. In contrast, no significant differences were observed between the males and females of the same age (Tables 3 and 4). Results of the current study revealed significant differences ( $P < 0.05$ ) among three types of infestation (single, double, and mixed).

## Discussion

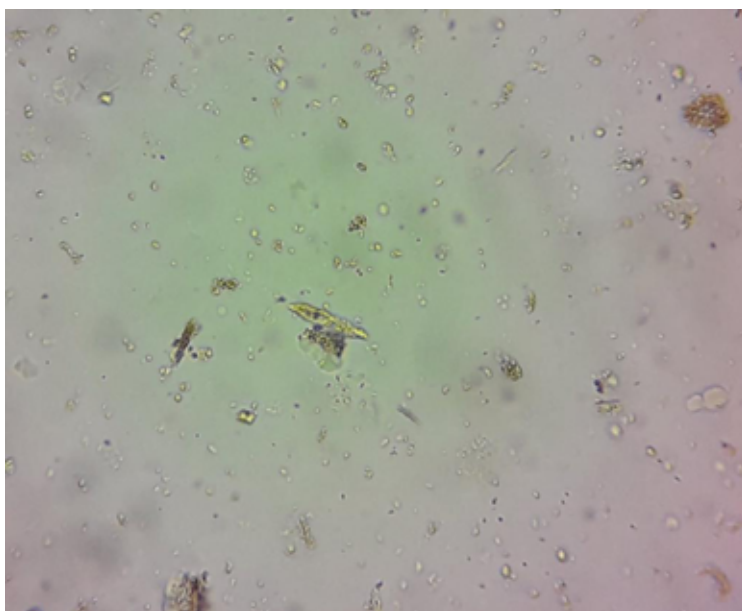
Mites cause highly contagious skin diseases in rabbits, which influence these animals' health and productive capacity in many countries (Sant & Rowland, 2009). The present study distinguished the morphological charac-



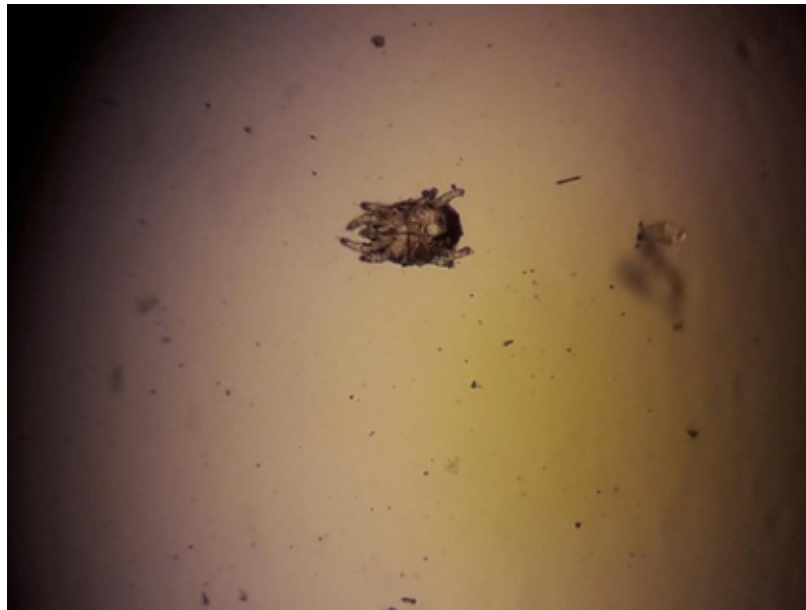
**Figure 1.** *S. scabiei cuniculi* (using a digital camera)

teristics of *S. scabiei* var. *cuniculi*, such as size, which ranged between 320-500  $\mu\text{m}$  in length and 250-410  $\mu\text{m}$  in width. These results agreed with that of [Elshahawy et al. \(2016\)](#), who found that the size of *S. scabiei* var. *cuniculi* was 300-504  $\mu\text{m}$  in length and 230-420  $\mu\text{m}$  in width. Psoroptes cuniculi have an oval body shape with pointed mouth parts, as described by [Nonga and Mkula \(2015\)](#). Results of the current study revealed other morphological characteristics of *N. cati* var. *Notoedres cati*, *D. cuniculi*, and *Cheyletiella* spp, which were similar to those found by [Elshahawy et al. \(2016\)](#).

The results of this study clarified that the percentage of infestation with *S. scabiei* var. *cuniculi* was 38.5%, which was too close to the infestation rate with the same mite on sheep (34.6%) and on rabbits (41.6%) as reported by [Shahatha et al. \(2022\)](#) whereas the infestation rate with *Psoroptes cuniculi*, *N. cati* var. *cuniculi*, *D. cuniculi* and finally *Cheyletiella* spp. were 25%, 20%, 9%, and 3%, respectively. However, these rates disagreed with the results of [Hoshem \(2014\)](#), who stated that the percentages of *P. cuniculi*, *N. cati*, and *Cheyletiella* spp. were 7.55%, 3.43%, and 1.51%, respectively. These dif-



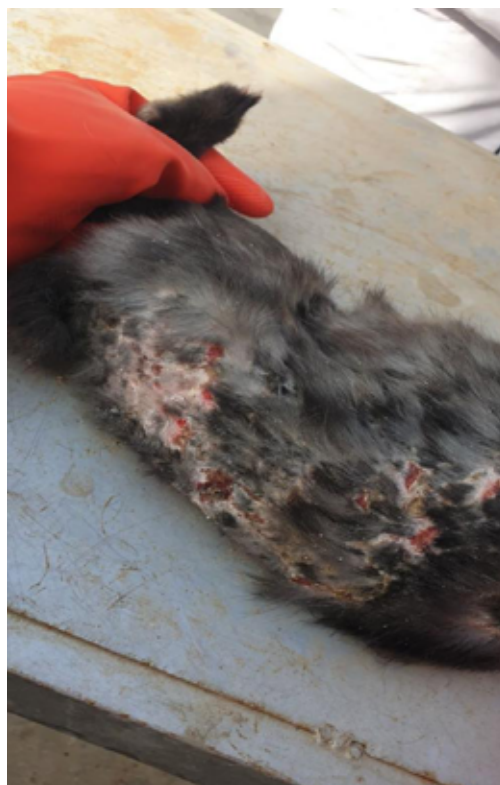**Figure 2.** *D. cuniculi* (using digital camera, x40 magnification)



**Figure 3.** *Cheyletiella* spp. (using digital camera, x40 magnification)

ferences could be attributed to the number of animals examined and the management's performance. On the other hand, our results agreed with [Shahatha et al. \(2022\)](#), who reported that the infestation rate with *S. scabiei* in cows was 37.5%. The most frequent lesions in rabbits were hyperkeratosis on the head and ears (26.8%), then

the abdomen and back (57.1%), and finally on the legs (44.6%), while the alopecia came in the second place after hyperkeratosis and its rates are 26.8% on the head and ears, 57.1% on the abdomen and back, and 19.6% on the tail and perineal areas.



**Figure 4.** Hyperkeratosis and alopecia on animal's back

**Table 1.** Infestation rate and morphological characteristics of mange based on mite species of infected rabbits

Species of Mites	No. (%)		Morphological Characteristic
	Infestation Rate		
<i>S. scabiei</i> var. <i>cuniculi</i>	50	(38.5)	Oval, dorsally convex, and ventrally flattened, size (320-500 μm in length) (and 250-410 μm in width), the final segment of the 1 <sup>st</sup> and 2 <sup>nd</sup> legs have elongated, unjointed empodium, which had a pint-size sucker-like pad at the terminal edges
<i>P. cuniculi</i>	32	(25)	Oval body, mouth parts pointed, Jointed pedicles with funnel-shaped suckers.
<i>N. cati</i> var. <i>cuniculi</i>	26	(20)	The small size was 230x200 μm with rounded idiosomic; the first and the second legs have pretarsal and elongated stalked, while the third and fourth legs had long bristle
<i>D. cuniculi</i>	12	(9)	Approximately 224 μm in length with long fusiform bodies
<i>Cheyletiella</i> spp.	4	(23)	Size 0.5 mm in length with prominent curved, palpal claws that point inwards, the important feature is the characteristic hooks of the accessory mouthparts

**Table 2.** The infestation rate and the common lesions in symptomatic rabbits according to the site of infestation

Site of Infestation	No.		Type of Lesion
	Infested Rabbits	Infestation Rate	
Head, ears	15	26.8	Alopecia+pruritus+hyperkeratosis
Abdomen, back	32	57.1	Alopecia+pruritus+hyperkeratosis
Legs	25	44.6	Hyperkeratosis
Tail and perineal area	11	19.6	Alopecia

**Table 3.** Incidence of mange mites according to the age and sex of examined rabbits

Sex	Age (y)	Male			Female		
		No.		%	No.		%
		Examined	Infestation		Examined	Infestation	
≤1	25	17	68 <sup>a</sup>	30	19	63.3 <sup>a</sup>	
>1	31	9	29 <sup>b</sup>	44	11	25 <sup>b</sup>	
Total	56	26	46.4 <sup>*</sup>	74	30	40.5 <sup>*</sup>	

<sup>a, b</sup>Significant differences at P≤0.05, <sup>\*</sup>No significant differences at P≤0.05.

**Table 4.** Types of mange infestation in the rabbits

Type of Infestation	No.		%
	Infested Rabbits	Infestation Rate	
Single	9	16.1 <sup>a</sup>	
Double	28	50 <sup>b</sup>	
Mixed	19	33.9 <sup>c</sup>	

<sup>a, b, c</sup>Different significant at P≤0.05.



Pruritus was the third noticed lesion on the infested animals, especially in the head and ears (26.8%) and then the abdomen and back (57.1%). These results agreed with those reported by [Shahatha et al. \(2022\)](#), who concluded that hyperkeratosis had the highest lesion rate at 40% while pruritus had the lowest at 20%. This study showed that the youngest animals had a greater infestation rate than those above one-year-old. The infestation rates were 68% for males and 63.3% for females under one-year-old (youngest animals), while 29% for males and 25% for females more than one year old. Our results were similar to the findings of [Elshahawy et al. \(2016\)](#), who reported a higher infection rate in younger rabbits (29%) compared to oldest animals (19.3%). This result could be attributed to keeping more than several age groups of animals together, which might have infestation via direct contact.

The results of the current study revealed no significant differences between males (46.4%) and females (40.5%) regarding the infestation rates with mange, which agreed with the results of [Shahatha et al. \(2020\)](#) and [Arul Prakash et al. \(2017\)](#). Finally, this research found significant differences among three types of infestations (single, double, and mixed). The double one had the highest rate at 50%, followed by mixed infestation at 33.9%, and finally, the single one had 16.1%. These results closely resembled those obtained by [Choe et al. \(2020\)](#) and [Ammam et al. \(2022\)](#), who showed that rabbits could infest with more than one species of mange mites simultaneously.

## Conclusion

The rabbits of Mosul City were infested with several species of the mange with different percentages. It is necessary to establish control via treatment with potent drugs and maintain the hygiene of the rabbit's environment. Also, the most vulnerable age group to the many species of mange mites was less or equal to one year.

## Ethical Considerations

### Compliance with ethical guidelines

Ethical approval was issued by the Institutional Animal Care and Use Committee, the College of Veterinary Medicine, [University of Mosul](#), on October 2, 2022 (Code: UM.VET.2022.20),

## Funding

This research did not receive any grant from funding agencies in the public, commercial, or non-profit sectors.

## Authors' contributions

All authors equally contributed to preparing this article.

## Conflict of interest

The authors declared no conflict of interest.

## Acknowledgments

The authors would like to thank the College of Veterinary Medicine, [University of Mosul](#).

## References

- Abdelaziz, A. R., Khakafalla, R. E., El khatam, A., Osman, A. E., & Abdel Mageed, N. (2020). Field study to evaluate the tropical application of deltamethrin, cyfluthrin and sulfur efficacy against sarcoptic mange of rabbit. *Alexandria Journal of Veterinary Sciences*, 67(2), 1-8. [DOI:10.5455/ajvs.25628]
- Abu Hafsa, S. H., Senbill, H., Basyony, M. M., & Hassan, A. A. (2021). Amelioration of sarcoptic mange-induced oxidative stress and growth performance in ivermectin-treated growing rabbits using turmeric extract supplementation. *Animals*, 11(10): 2984. [DOI:10.3390/ani11102984] [PMID]
- Altamey, A. A. (2014). Natural infection and treatment of domestic rabbit mange. *Journal of Wassit For Science & Medicine*, 7(4), 142-148. [Link]
- Ammam, I., Rahal, M., Rahal, K., & Bitam, I. (2022). Epidemiological study and identification of some flea species infesting wild rabbits (*Oryctolagus cuniculus*) and cape hares (*Lepus capensis*) in northern Algeria. *Iraq Journal veterinary Science*, 36(1), 159-165. [DOI:10.33899/ijvs.2021.129596.1665]
- Asmare, K., Abebe, R., Sheferaw, D., Krontveit, R. I., & Barbara, W. (2016). Mange mite infestation in small ruminants in Ethiopia: Systematic review and meta-analysis. *Veterinary Parasitology*, 218, 73-81. [DOI:10.1016/j.vetpar.2016.01.017] [PMID]
- Cardells, J., Lizana, V., Martí-Marco, A., Lavín, S., Velarde, R., & Rossi, L., et al. (2021). First description of sarcoptic mange in an Iberian hare (*Lepus granatensis*). *Current Research in Parasitology & Vector-Borne Diseases*, 1, 100021. [DOI:10.1016/j.crvbd.2021.100021] [PMID]
- Choe, S., Kim, S., Na, K. J., Nath, T. C., Ndosi, B. A., & Kang, Y., et al. (2020). First infestation case of sarcoptic mange from a pet rabbit *Oryctolagus cuniculus* in Republic of Korea. *The Korean Journal of Parasitology*, 58(3), 315-319. [DOI:10.3347/kjp.2020.58.3.315] [PMID]

- Elshahawy, I., El-goniemy, A., & Esraa, A. (2016). Epidemiological survey on mange mite of rabbits in the Southern Region of Egypt. *Sains Malaysiana*, 45(5),745-751. [Link]
- Hoshem, S. A., Mahrous, L. N., Abded-kafy, E. M., & Abo-Elhadid, S. M. (2014). Some mite species infecting rabbits with a trail for in vitro control. *Egyptian Veterinary Medical Society of Parasitology Journal*, 10, 77-85. [Link]
- Kumsa, B., Beyecha, K., & Geloye, M. (2012). Ectoparasites of sheep in three agroecological zones in central Oromia, Ethiopia. *The Onderstepoort Journal of Veterinary Research*, 79(1), E1-E7. [DOI:10.4102/ojvr.v79i1.442] [PMID]
- León-Vizcaíno, L., Ruíz de Ybáñez, M. R., Cubero, M. J., Ortíz, J. M., Espinosa, J., & Pérez, L., et al. (1999). Sarcoptic mange in Spanish ibex from Spain. *Journal of Wildlife Diseases*, 35(4), 647-659. [DOI:10.7589/0090-3558-35.4.647] [PMID]
- Nonga, H. E., & Mkula, S. R. (2015). Rabbit management and occurrences of mange mite infestations in rabbit farms in morogoro municipality, Tanzania. *Tanzania Veterinary Journal*, 30(2), 28-40. [Link]
- Nuru, H. B., & Mhatebu, W. T. (2017). Prevalence of mange mites on small ruminants in Haramaya Wereda (District), East Hararge Zone, Ethiopia. *International Journal of Research-GRANTHAALAYAH*, 5(4), 191-201. [DOI:10.29121/granthaalayah.v5.i4.2017.1812]
- Ola -Fadunsin, S. D., Abdulrauf1, A. B., Ganiyu, I. A., Hussain, K., Ambali, H. M., & Elelu, N. (2023). The intensity of infection and public health perception of potentially zoonotic intestinal parasites of dogs in Kwara Central, Nigeria. *Iranian Journal Veterinary Medicine*, 17(2), 119-128. [DOI:10.32598/IJVM.17.2.1005295]
- Arul Prakash, M., Soundararajan, C., Nagarajan, K., Tensingh Gnanaraj, P., & Ramesh Saravanakumar, V. (2017). Sarcoptic mange infestation in rabbits in an organized farm at Tamil Nadu. *Journal of Parasitic Diseases*, 41(2), 429-432. [DOI:10.1007/s12639-016-0821-2] [PMID]
- Rao, N., Parmar, J. J., Sadhu, D. B., Shah, A. I., & Patel, D. M. (2020). Sarcoptic mange and its successful therapeutic management in rabbits. *The Indian Journal of Veterinary Sciences and Biotechnology*, 15(3), 70-73. [Link]
- Rodrigues , C. S. M. P. , Rahal, S. C. , Silva Júnior, J. I. S. , Silva, J. P., Mamprim, M. J., & Figueroa, J. G., et al. (2022). Characteristics of fractures of the appendicular and axial skeletons in rabbits and hares: A retrospective study. *Iranian Journal Veterinary Medicine*, 16(4), 338-347. [Link]
- Sant, R., & Rowland, M. (2009). Skin diseases in rabbits. *In Practice*, 31, 233-238. [DOI:10.1136/inpract.31.5.233]
- Seddiek, S. A., Khater, H. F., El-shorbagy, M. M., & Ali, M. (2013). The acaricidal efficacy of aqueous neem extract and ivermectin against *Sarcoptes scabiei* var. *cuniculi* in experimentally infested rabbits. *Parasitology Research*, 112(6), 2319-2330. [DOI:10.1007/s00436-013-3395-2] [PMID]
- Shahatha, S. H. (2020). Epidemiological, diagnostic and therapeutic study for mange in sheep of anbar province-Iraq. *Iraqi Journal of Veterinary Sciences*, 34(1), 1-7. [DOI:10.33899/ijvs.2020.163587]
- Shahatha, Sh., Ayyed, I. M., & Mousa, M. O. (2022). An epidemiological and therapeutic study of *Sarcoptes scabiei* parasite of Anbar province, Iraq. *Iraqi Journal of Veterinary Sciences*, 36(1), 103-109. [Link]
- Solikhah, T. I., Solikhah, G. P., & Susilo, R. K. (2021). Aloe Vera and vergin coconut oil (VCO) accelerate healing process in domestic cat (*felis domesticus*) suffering from scabies. *Iraqi Journal of Veterinary Sciences*, 35(4), 699-704. [DOI:10.33899/ijvs.2020.127884.1539]
- Taylor, M. A., Coop, R. L., & Wall, R. (2016). *Veterinary parasitology*. New Jersey: Wiley Blackwell. [Link]
- Yasine, A., Kumsa, B., Hailu, Y., & Ayana, D. (2015). Mites of sheep and goats in Oromia Zone of Amhara Region, North Eastern Ethiopia: Species, prevalence and farmers awareness. *BMC Veterinary Research*, 11, 122. [DOI:10.1186/s12917-015-0433-6] [PMID]

This Page Intentionally Left Blank