

Original Article

Morphological and Molecular Detection of *Dicrocoelium dendriticum* Infection in RuminantsNadia Hamid Mohammed* , Wassan Amjad Alobaidii 

Department of Microbiology, College of Veterinary Medicine, University of Mosul, Mosul, Iraq.



How to Cite This Article Mohammed, N. H., & Alobaidii, W. A. (2024). Morphological and Molecular Detection of *Dicrocoelium dendriticum* Infection in Ruminants. *Iranian Journal of Veterinary Medicine*, 18(1), 51-58. <http://dx.doi.org/10.32598/ijvm.18.1.1005360>

 <http://dx.doi.org/10.32598/ijvm.18.1.1005360>

**ABSTRACT**

Background: Dicrocoeliosis is a parasite disease that affects the liver of domestic and wild ruminants. It is one of the challenges in the livestock industry that causes significant diseases and economic losses.

Objectives: This study aimed to identify *Dicrocoelium dendriticum* in sheep and cattle using their morphological and molecular characteristics.

Methods: The current study examined 122 sheep and cattle livers from both sexes slaughtered in butcher shops. Found worms were selected randomly from the livers of sheep and cattle. They were stained for parasite morphometric measurements studies and macroscopic examination of the liver considering the color, consistency, and size. Molecular methods confirm the diagnosis of *D. dendriticum* in cattle and sheep.

Results: The infection rates of *D. dendriticum* parasite in sheep and cattle were 34.4% and 10.7% respectively. The results showed a significant difference in the infection rate between sheep and cattle, while there is no significant difference between females and males in both sheep and cattle. Macroscopic diagnosis of the infected livers showed discoloration, swelling, wrinkled needle-spot shape and hyaline, the sharpness of liver margins loss, and biliary fibrosis. *D. dendriticum* was morphologically identified in all specimens collected from the sheep and cattle. The molecular examination confirmed the diagnosis of these parasites, which belonged to the species *D. dendriticum*, with a product reaction of 900 base pairs.

Conclusion: This study is the first to isolate and detect *D. dendriticum* in sheep and cattle and to overview the genotype compositions of *D. dendriticum*.

Keywords: *Dicrocoelium dendriticum*, Dicrocoeliosis in sheep, Dicrocoeliosis in cattle, Lancet liver fluke, PCR of Dicrocoelium

Article info:

Received: 25 Mar 2023

Accepted: 14 Jun 2023

Publish: 01 Jan 2024

*** Corresponding Author:**

Nadia Hamid Mohammed, Assistant Professor.

Address: Department of Microbiology, College of Veterinary Medicine, University of Mosul, Mosul, Iraq.

E-mail: nadiahamid@uomosul.edu.iq

Introduction

Dicrocoelium dendriticum, called lancet liver fluke, is a common parasitic liver and gall bladder disease in wild and domestic animals. It is also observed in horses, camels, rabbits, pigs, and humans (Scala et al., 2019). In addition, the human infection rate has increased in recent years (Jafari Rad et al., 2022; Abdollahpour et al., 2023). *D. dendriticum* is an important species in economic industries and veterinary medicine (Arbabi et al., 2018). Dicrocoelium has a complicated life cycle (Iyaji et al., 2018; Hosseini et al., 2022). Its first intermediate hosts are various species of snails, and its second intermediate hosts are various species of ants. The disease can cause diarrhea, weight loss, anemia, digestive disorders, edema, growth delay, reduced milk production, biliary obstruction cholangitis, acute urticarial, and cirrhosis (Ofori et al., 2015). Dicrocoeliosis, a food-borne zoonotic disease, is caused by three species of Dicrocoelium, including *Dicrocoelium hospes* and *Dicrocoelium chinensis* (Khan et al., 2023). *D. hospes* is an endemic disease in West Africa, *D. chinensis* in Europe and eastern Asia, and *D. dendriticum* endemic in Asia, Europe, North Africa, and America (Chougar et al., 2019; Lianou et al., 2023). This study aimed to characterize the morphology and molecular characteristics of the parasite *D. dendriticum* in cattle and sheep and to detect its various species in these animals.

Materials and Methods

Sample collection

A total of 122 liver samples were taken from 64 sheep and 58 cattle slaughtered in the different areas in Mosul City for both sexes. The found worms were placed in 70% ethanol alcohol and stored at -20°C for the polymerase chain reaction technique (Mahdee et al., 2022).

Morphological examination

Fifteen adult worms were selected randomly from the livers of sheep and cattle. The worm was placed between two glass slides, treated with formalin acetic acid alcohol solution, stained with hematoxylin, and mounted in Canada balsam (Ebrahim Pour et al., 2020). Morphometric measurements of parasites were performed under the light stereo microscope according to the study by Jwher et al. (2021). The macroscopic examination of the liver involved its color, consistency, and size (Makawi et al., 2023; Kadhum et al., 2022).

DNA extraction

According to the manufacturer's instructions, the DNA of 20 worms was extracted using a pure column DNA extraction kit, Bioron. Restriction fragment length polymorphism (RFLP)-PCR was performed to detect the DNA of *D. dendriticum*. The amplification of DNA was done using a specific primer to *D. dendriticum*, NADH dehydrogenase subunit gene (*nad1*), the primer Forward (5'-TTAAAACACACCCAC-CAGAA-3'), and primer reverse (5'-GTGTTTTGGTT-TAATGTTTT-3') (Gorjipoor et al., 2015). The reaction solution of 25 µL contained 5 µL of DNA extracted. Then, 1 µL of each primer, 12 µL of mater mix (IDAA™-kit), and 6 µL of distilled water were mixed. The amplification program includes keeping at 95°C for 5 minutes with 30 cycles at 95°C for 2 minutes, at 58.4°C for 1 minute, and 72°C for 2 minutes. Final amplification products were diagnosed using 1% agarose gel electrophoresis (900 bp), after which 2 µL of Thermo Scientific™ FastDigest Green Buffer (10 x) (Thermo Fisher Scientific Inc.) was added to 10 µL of PCR mix with 18 µL of distilled water. Afterward, the mixture was incubated for 40 minutes at 37°C. The reaction products (206 and 694 bp) were analyzed by 1% agarose gel electrophoresis (Shokouhi et al., 2018).

Statistical analysis

Statistical analysis was done using the chi-square test in SPSS software, version 17 (SPSS Inc., Chicago, USA).

Results

The infection rate of *D. dendriticum* was 23%, and the infection rates in sheep and cattle were 34.4% and 10.7%, respectively. The results show a significant difference in infection in both sheep and cattle. The results are not significant at $P < 0.05$ between males and females for both sheep and cattle (Table 1). Morphometric measurements of *D. dendriticum* in sheep and cattle are presented in Table 2. It also shows that the mean of the internal-external diameter of the oral and ventral suckers, in addition to diameters of testes, vitelline glands (length, width), and the testes orientation in the *D. dendriticum* (Tandem testes) (Figures 1 and 2). The current study clarifies that *D. dendriticum* is the only species isolated from sheep and cattle, according to morphometric and molecular studies. Macroscopic diagnosis of the infected livers shows discoloration, swelling, wrinkled spots, hyaline and biliary fibrosis, and lack of sharpness of liver margins (Figure 3). In

Table 1. The infection rate of *D. dendriticum* among slaughtered sheep and cattle in Mosul City, Iraq

Animal Type	No.				Infection Rate (%)		
	Examined Animals		Infected Animals		Male	Female	Total
	Male	Female	Male	Female			
Sheep	30	34	9	13	30 ^a	38.2 ^a	34.4*
Cattle	25	33	2	4	8 ^b	12.1 ^b	10.7*
Total	55	67	11	17	20	25.4	23

*Significant differences between sheep and cattle ($P < 0.05$), ^aNo significant difference between females and males in sheep,

^bNo significant difference between females and males in cattle.

addition, many flukes are detected in the liver’s bile ducts. As for the results of molecular analysis, the amplification of DNA of worms by using PCR-RFLP used a specific primer of *D. dendriticum* nad1 fragment (900 bp), and then digestion to produce 206 and 694 bp fragments. All samples were positive for *D. dendriticum* (Figure 4).

Discussion

Dicrocoeliosis is one of the important parasitic diseases in veterinary medicine that infects the livers of domestic and wild animals (Kleiman et al., 2007). According to the current study, the percentages of infected sheep and cattle slaughtered were 34.4% and 10.7%, respectively, with significant differences. These results

agree with the previous study from another country by Ebrahim Pour et al. (2020), which declared that the infection percentages in sheep and cattle were 36.7% and 6.09%, respectively. Ahmadi and Mahdavi (2010) reported that the infection percentages in sheep and cattle were 22.4% and 4.5%, respectively. The differences in the percentage of *D. dendriticum* in Iraq are probably due to the grazing behavior, environmental conditions, and management system. In addition, the current study evaluated the influence of sex for the host on *D. dendriticum* and found no statistically significant difference for the sex in the percentages of this infection (Maurelli et al., 2007).

All specimens collected from the sheep and cattle were morphologically identified as *D. dendriticum*

Table 2. Morphometric measurements of *D. dendriticum*, the characteristics of 50 flukes (25 from sheep and 25 from cattle)

Variables	Mean±SD	
	Sheep (Min-Max)	Cattle (Min-Max)
Length (body) (mm)	4.10-5.10 (4.80±1.40)	7.02-9.01 (5.20±1.50)
Width (body) (mm)	1.05-1.60 (2.27±1.12)	1.20-2.50 (160.20±31.50)
The internal diameter of the oral sucker (µm)	170-188 (119.50±20.6)	120-300 (160.20±31.50)
The external diameter of the oral sucker (µm)	298-325 (216.21±12.3)	300-400 (230.20±31.45)
The internal diameter of the ventral sucker (µm)	200-260 (216.21±12.3)	120-220 (130±25.10)
The external diameter of the ventral sucker (µm)	300-460 (332±21.65)	300-550 (250.11±42.10)
Length of testicle (µm)	490-700 (451±44.8)	460-850 (650.10±78.15)
Width of testicle (µm)	340-500 (500±40.33)	500-700 (600±70.61)
Length of vitelline gland (mm)	1.10-2.2 (1.80±1.23)	1.25-3.20 (2.52±1.02)



Figure 1. Severe infection with *D. dendriticum*, worms isolated from the bile ducts of sheep's liver

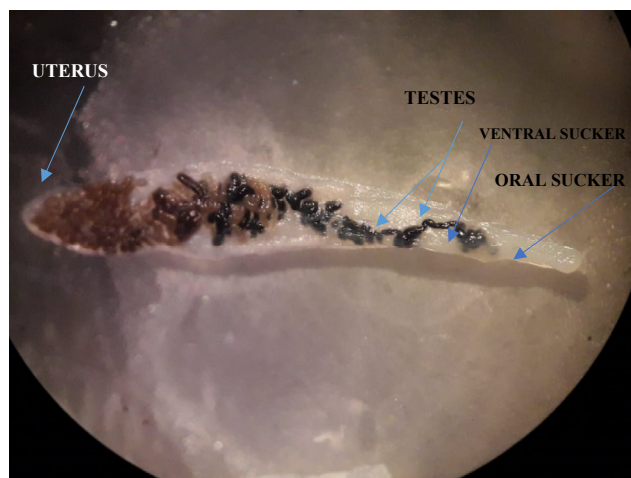


Figure 2. *D. dendriticum*, under the dissecting microscope

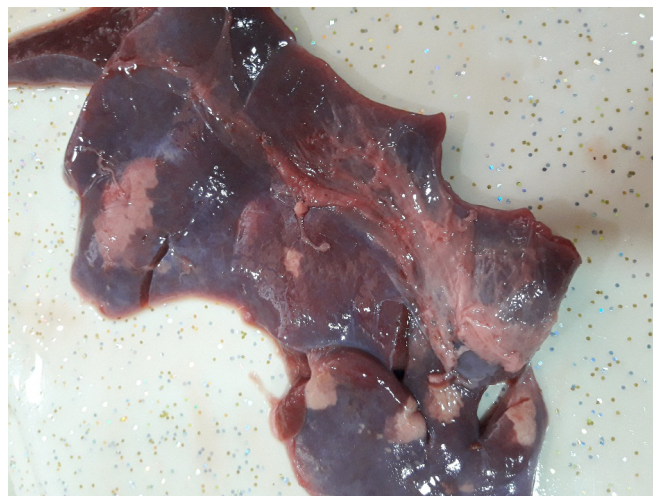

Figure 3. Livers infected showing discoloration, swelling, hyaline, the sharpness of liver margins loss and biliary fibrosis




Figure 4. Gel electrophoresis image

Lane (M) & lanes: 2, 5, 8): Negative samples to *D. dendriticum* DNA; Lanes (1, 3-4, 6-7 and 9): Positive samples to *D. dendriticum* DNA in approximately band size 900 bp.

based on the measurement and morphological keys, such as body length, maximum body width, testes orientation, and other morphometric measurements, and this result agreed with [Sandoval et al. \(2013\)](#) study. In addition, other studies in Austria, Italy, and Germany showed that the location of testes in *D. dendriticum* determined the species of *Dicrocoelium*. The testicles of *D. dendriticum* are tandem but bilateral in *D. chinensis* ([Javanmard et al., 2022](#)). This finding is in agreement with our current study. The macroscopic observation of infected livers aligned with the results described by [Liu et al. \(2014\)](#). [Manga Gonzalez et al. \(2010\)](#) showed discoloration, swelling, hyaline, change of liver margins, and biliary fibrosis. The results of the molecular techniques of this current study agree with the results described by [Gorjipoor et al. \(2015\)](#). However, according to morphometric measurements and molecular techniques, *D. dendriticum* exclusively causes diploidosis in sheep and cattle in Mosul, Iraq.

Conclusion

This study is the first to identify *D. dendriticum* in Mosul City, Iraq. The information gathered from the current research will reveal the rate of *D. dendriticum* infection in Iraq. Moreover, these parasites must be molecularly identified to be controlled and prevented.

Ethical Considerations

Compliance with ethical guidelines

Ethical approval was issued by the Institutional Animal Care and Use Committee of the College of Veterinary Medicine, [University of Mosul](#) on September 6, 2022 (Code: UM.VET.2022.16).

Funding

This research did not receive any grant from funding agencies in the public, commercial, or non-profit sectors.

Authors' contributions

All authors equally contributed to preparing this article.

Conflict of interest

The authors declare no conflict of interest.

Acknowledgments

All authors thanks of College of Veterinary Medicine, [University of Mosul](#).

References

- Abdollahpour, G., Abdollahi, M., Seidi Samani, H., Jani, M., & Rezaei Tuseh Kaleh, M. (2023). Report of the occurrence of schistosomus reflexus in a goat kid. *Iranian Journal of Veterinary Medicine*, 17(2), 183-188. [DOI:10.32598/IJVM.17.2.1005222]
- Ahmadi, R., Mahdavi, E., & Maleki, M. (2010). Prevalence of dicrocoelium dendriticum, infection in cattle, sheep and goat in Gilan Province, Northern Iran. *Journal of Animal and Veterinary Advances*, 9(21), 2723-272. [DOI:10.3923/javaa.2010.2723.2724]
- Arbabi, M., Nezami, E., Hooshyar, H., & Delava, M. (2018). Epidemiology and economic loss of fasciolosis and dicrocoeliosis in Arak, Iran. *Veterinary World*, 11(12), 1648-1655. [DOI:10.14202/vetworld.2018.1648-1655] [PMID]
- Chougar, L., Harhoura, K., & Aissi, M. (2019). First isolation of Dicrocoelium dendriticum among cattle in some Northern Algerian slaughterhouses. *Veterinary World*, 12(7), 1039-1045. [DOI:10.14202/vetworld.2019.1039-1045] [PMID]
- Ebrahim Pour, M. H., Shemshadi, B., Bahrami, A., & Shirali, S. (2020). Molecular identification of Dicrocoelium dendriticum, using 28s rDNA genomic marker and its histopathologic features in domestic animals in western Iran. *Journal of Basic Research in Medical Sciences*, 7(4), 43-52. [Link]
- Gorjipoor, S., Moazeni, M., & Sharifiyazdi, H. (2015). Characterization of Dicrocoelium dendriticum, haplotypes from sheep and cattle in Iran based on the internal transcribed spacer 2 (ITS-2) and NADH dehydrogenase gene (nad1). *Journal Helminthology*, 89(2), 158-164. [DOI:10.1017/S0022149X13000679] [PMID]
- Hosseini, M., Sanjarani, Z., Nabavi, R., Shariati Sharifi, F., & Davari SA. (2022). Morpho-molecular characterization of cattle haemonchus nematodes from southeast of Iran. *Iranian Journal of Veterinary Medicine*, 16(4), 364-371. [DOI:10.22059/IJVM.2021.318533.1005157]
- Javanmard, E., Mohammad Rahimi, H., Nemati, S., Soleimani Jevinani, S., & Mirjalali, H. (2022). Molecular analysis of internal transcribed spacer 2 of Dicrocoelium dendriticum isolated from cattle, sheep, and goat in Iran. *BMC Veterinary Research*, 18(1), 283. [DOI:10.1186/s12917-022-03386-2] [PMID]
- Jwher, D. M., Jarjees, M. T., & Shareef, A. M. (2021). A study of the gastrointestinal parasites in Awassi sheep and surrounding environment. *Iraqi Journal of Veterinary Sciences*, 35(3), 561-567. [DOI:10.33899/ijvs.2020.127174.1478]
- Khan, M. A., Afshan, K., Sargison, N. D., Betson, M., Firasat, S., & Chaudhry, U. (2023). Spatial distribution of dicrocoelium in the Himalayan Ranges: Potential impacts of ecological niches and climatic variables. *Acta Parasitologica*, 68(1), 91-102. [DOI:10.1007/s11686-022-00634-1] [PMID]
- Khanjari, A., Bahonar, A., Fallah, S., Bagheri, M., Alizadeh, A., & Fallah, M., et al. (2014). Prevalence of fasciolosis and dicrocoeliosis in slaughtered sheep and goats in Amol Abattoir, Mazandaran, Northern Iran. *Asian Pacific Journal of Tropical Disease*, 4(2), 120-124. [DOI:10.1016/S2222-1808(14)60327-3]
- Kleiman, F., Pietrokovsky, S., Prepelitchi, L., Carbajo, A. E., & Wisnivesky-Colli, C. (2007). Dynamics of Fasciola hepatica transmission in the Andean Patagonian valleys Argentina. *Veterinary Parasitology*, 145(3-4), 274-286. [DOI:10.1016/j.vetpar.2006.12.020] [PMID]
- Lianou, D. T., Arsenopoulos, K. V., Michael, C. K., Mavrogiani, V. S., Papadopoulos, E., & Fthenakis, G. C. (2023). Helminth infections in dairy sheep found in an extensive countrywide study in Greece and potential predictors for their presence in faecal samples. *Microorganisms*, 11(3), 571. [DOI:10.3390/microorganisms11030571] [PMID]
- Liu, G. H., Yan, H. B., Otranto, D., Wang, X. Y., Zhao, G. H., & Jia, W. Z., et al. (2014). Dicrocoelium chinensis and Dicrocoelium dendriticum, are distinct lancet fluke species based on mitochondrial and nuclear ribosomal DNA sequences. *Molecular Phylogenetics and Evolution*, 79, 325-331. [DOI:10.1016/j.ympev.2014.07.002] [PMID]
- Kadhun, N. K., Karim, S. M., Mansour, K. A., & Alfatlawi, M. A. (2022). Indicative parameters for liver fascioliasis at pre-clinical and clinical phases in cows from Al-Diwaniyah city, Iraq. *Iraqi Journal of Veterinary Sciences*, 36(3), 653-657. [DOI:10.33899/ijvs.2022.132266.2076]
- Makawi, Z. A. (2023). Isolation and identification of intestinal parasites from Goats in some areas of Wasit Province, Iraq. *Revis Bionatura*, 8 (1), 39. [DOI:10.21931/RB/2023.08.01.39]
- Manga Gonzalez, M., Quiroz Romero, H., Gonzalez Lanza, C., Minambres, B., & Ochoa, P. (2010). Strategic control of Dicrocoelium dendriticum, egg excretion by naturally infected sheep. *Veterinary Medicine*, 55(1), 19-29. [DOI:10.17221/63/2009-VETMED]
- Maurelli, M. P., Rinaldi, L., Capuano, F., Perugini, A. G., Veneziano, V., & Cringoli, G. (2007). Characterization of the 28S and the second internal transcribed spacer of ribosomal DNA of Dicrocoelium dendriticum, and Dicrocoelium hospes. *Parasitology Research*, 101(5), 1251-1255. [DOI:10.1007/s00436-007-0629-1] [PMID]
- Ofori, M., Bogoch, I. I., & Ephraim, R. K. (2015). Prevalence of dicrocoelium dendriticum ova in Ghanaian school children. *Journal of Tropical Pediatrics*, 61(3), 229-230. [DOI:10.1093/tropej/fmv015] [PMID]
- Iyaji, F. O., Yaro, C. A., Peter, M. F., & Abutu, A. E. O. (2018). Fasciola hepatica and associated parasite dicrocoelium dendriticum, in Slaughter houses in Anyigba, Kogi State, Nigeria. *Advances in Infectious Diseases*, 8(1), 1-9. [DOI:10.4236/aid.2018.81001]
- Jafari Rad, M., Navi, Z., Heidari, A. R., Lavi Arab, F., Tabasi, N., & Rastin, M., et al. (2022). Evaluation of the immunoregulatory effect of Dicrocoelium dendriticum eggs on inflammatory and anti-inflammatory cytokines in EAE model. *Parasite Immunology*, 44(10), e12942. [DOI:10.1111/pim.1294] [PMID]
- Sandoval, H., Manga-González, M. Y., & Castro, J. M. (2013). A tool for diagnosis of Dicrocoelium dendriticum, infection hatching eggs and molecular identification of the miracidium. *Parasitology Research*, 112(4), 1589-1595. [DOI:10.1007/s00436-013-3313-7] [PMID]

Scala, A., Tamponi, C., Dessì, G., Sedda, G., Sanna, G., & Carta, S., et al. (2019). Dicrocoeliosis in extensive sheep farms: A survey. *Parasites & Vectors*, 12(1), 342. [DOI:10.1186/s13071-019-3609-2] [PMID]

Shokouhi, S., Mirzaei, A., Naserifar, R., & Abdi, J. (2018). *Dicrocoelium dendriticum*, infection among livestock in Western Iran. *Southeast Asian Journal of Tropical Medicine and Public Health*, 49(5), 755-760. [Link]

This Page Intentionally Left Blank