

Original Article

Tumor Lesions in the Caspian White Fish (*Rutilus kutum*)Mohaddes Ghasemi^{1*}, Issa Sharifpour², Somayeh Haghighi Karsidani³, Zahra Eynizadeh⁴, Hasti Azarabad⁵

1. Inland Waters Aquaculture Research Center, Iranian Fisheries Science Research Institute (IFSRI), Agriculture Research Education and Extension Organization (AREEO), Bandar-e Anzali, Iran.

2. Iranian Fisheries Sciences Research Institute (IFSRI), Agricultural Research, Education and Extension Organization, Tehran, Iran.

3. Department of Fishery, Faculty of Natural Resources, Bandar Anzali Branch, Islamic Azad University, Bandar-e Anzali, Iran.

4. Department of Animal Sciences and Marine Biology, Faculty of Life Sciences and Biotechnology, Shahid Beheshti University, Tehran, Iran.

5. Department of Pathology, Hamidreza Fattahian Pet Hospital, Tehran, Iran.



How to Cite This Article Ghasemi, M., Sharifpour, I., Haghighi Karsidani, S., Eynizadeh, Z., & Azarabad, H. (2024). Tumor Lesions in the Caspian White Fish (*Rutilus kutum*). *Iranian Journal of Veterinary Medicine*, 18(2), 291-300. <http://dx.doi.org/10.32598/ijvm.18.2.1005373>

doi <http://dx.doi.org/10.32598/ijvm.18.2.1005373>

**ABSTRACT**

Background: Due to the multifactorial etiology, tumor manifestation in any vertebrate species may become a critical issue. This topic requires more consideration for species in aquatic ecosystems as an enclosed habitat. In addition, knowledge about oncogenesis in the aquaculture industry enhances the quality of products and its earned benefits.

Objectives: This study investigated the tumor lesions, their characteristics, and probable causes, in the most commercially important fish in the southern Caspian Sea: Caspian white fish (*Rutilus kutum*).

Methods: To accomplish this goal, after gross pathology of more than 20 cases, histopathological examinations and electron microscopic assays were employed.

Results: The findings confirmed squamous cell carcinoma and squamous cell papilloma in the examined cases. Furthermore, the virus-like particles were clearly observed in the transmission electron microscopy results, indicating the probable viral etiology for these neoplastic lesions in Caspian Kutum.

Conclusion: This study is the first to report the tumor prevalence in fish species of the southern Caspian Sea, which could be an alert for the mentioned ecosystem's health and the whole aquaculture industry.

Keywords: Caspian Sea, Fish neoplasm, Squamous cell carcinoma, Squamous cell papilloma, Tumor viruses

Article info:

Received: 16 Aug 2023

Accepted: 08 Nov 2023

Publish: 01 Apr 2024

*** Corresponding Author:**

Mohaddes Ghasemi, Assistant Professor:

Address: Inland Waters Aquaculture Research Center, Iranian Fisheries Science Research Institute (IFSRI), Agriculture Research Education and Extension Organization (AREEO), Bandar-e Anzali, Iran.

Phone: +98 (13) 44424055

E-mail: mohades@yahoo.com

Introduction

Caspian white fish (*Rutilus kutum*) (Kamensky, 1901), also known as Caspian Kutum, is a native and the most commercially important bony fish in the southern Caspian Sea. This cyprinid anadromous fish is distributed in the southern Caspian Sea basin, as the largest lake in the world, bordered with the Kura River in Azerbaijan, the Atrak River in Turkmenistan, and the Iranian coastal region (Mirzajani et al., 2016; Samavat et al., 2019). Based on 16 years study of beach seine fishing, Caspian white fish was identified as the most preyed fish in this area, serving as a critical indicator of fish species in the southern Caspian Sea ecosystem (Fazli & Parafkandeh Haghghi, 2016).

Therefore, investigating the pathogenic or life-threatening agents of this species is of utmost importance. Moreover, the accumulation of pathogens, as well as heavy metals and persistent organic compounds in edible piscine species, may be potentially hazardous to the ecosystem and public health, considering the epizootics of some pathogens between various species in the aquatic environment and in some cases between aquatics and human beings (Farrell et al., 2021; Goyal & Nelson, 1984). Viruses stand out as the most troubling among pathogens due to their prevalence and incurability. In addition, several tumor viruses cause cancer in warm-blooded and cold-blooded animals (Groff, 2004; Harshbarger et al., 2021).

The occurrence of neoplasia has been frequently documented in many freshwater and marine fishes, from 1916 of an epidermal papilloma in European smelt (*Osmerus eperlanus*) to now, with purely genetic or chemical carcinogenic origin as well as viral causes which more than half of them were reported as skin tumors (Baumann, 1992; Breslauer, 1916; da Rocha et al., 2018; Harshbarger & Clark, 1990).

This study provided the first report of proliferative skin lesions detected in Caspian white fish with suspected oncogenic viral etiology and the first report of neoplasm seen in a fish species of the southern Caspian Sea.

Materials and Methods

Sampling

Sampling was conducted during harvest season (October to April) from 43 different beach seine fishing.

The captured fishes (nearly 6000), all of which were *R. kutum*, were screened for abnormal signs and suspected samples and then were further delivered to “the reference virology laboratory for fish which belongs to Iranian Fisheries Science Research Institute (IFSRI),” for diagnostic examinations.

Histopathological examinations

After gross pathology and biometry of all samples, some with apparent signs of abnormal proliferative lesions on their lips were selected to be examined histopathologically. To accomplish this, tissues were excised and placed in conical tubes containing 10% buffered formalin solution that was refreshed after 24 hours. Before embedding in paraffin, the dehydration process of tissues was performed in ethanol concentration gradients of 50%, 70%, 90%, and 100%, cleared with chloroform. The 5- μ m sections were prepared from tissue samples using a rotary microtome. Afterward, staining was done using hematoxylin and eosin (H&E), and sections were examined by light microscope (Nikon Ci-L plus) according to the standard procedures.

Electron microscopy

To perform the electron microscopy, sections were prefixed for 2 hours at 4°C with 2.5% glutaraldehyde (TAAB laboratories-3 Minerva, Calleva Park, Aldermaston, Berks, RG78NA, England-EM grade) in 0.1 M phosphate buffer saline (PBS, pH=7.2). The prepared sections were washed three times in the PBS (10 min for each time). After washing, they were post-fixed in 0.5% osmium tetroxide (TAAB laboratories-3 Minerva) in the same buffer at room temperature for 1 hour. The samples were dehydrated in ascending alcohol series, acetone, and acetone-resin mixture (50/50), embedded in TAAB embedding resin (TAAB laboratories-3 Minerva), and polymerized at 60°C for 48 hours. Next, 50-nm ultra-thin sections were then prepared by Lika Ultracut R (Lika, Wetzlar, Germany), placed on a 300 mesh copper grid and double stained with 20% uranyl acetate (BDH Laboratory Chemicals Division, England, No. 0148860) for 45 min in pure methanol (E. Merck, D-6100 Darmstadt) and Reynolds solution (lead nitrate and sodium citrate; (Reynolds, 1963) for the same time. Finally, the samples were examined with the Transmission Electron Microscope (EM208S, PHILIPS, Netherlands) at the accelerating voltage of 100 kV.



Figure 1. Gross pathology of abnormal mouth cutaneous neoplasia in *R. kutum*

a and b) Cases with squamous cell papilloma, c and d) Cases with squamous cell carcinoma

Results

Gross pathology

During gross pathology examinations of specimens, 22 were diagnosed with definite cutaneous neoplasms. Specimens have flat, round, or oval cauliflower-shaped bumps only on the upper jaw and, in some cases, on both jaws in front of their lip. The diameter of lesions on the lips varied from 0.5×0.5 cm to 4×2 cm, and their color was similar to the surrounding skin or a bit lighter (Figure 1).

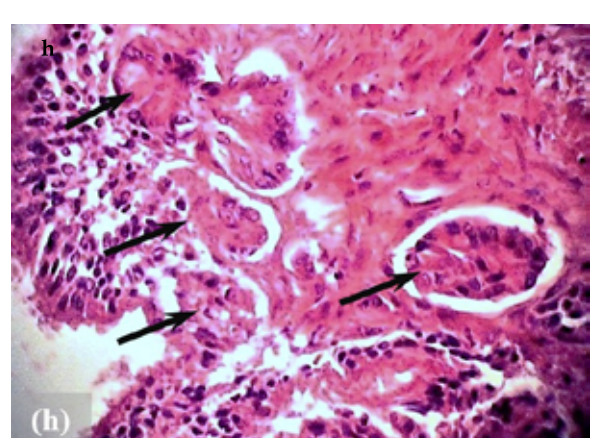
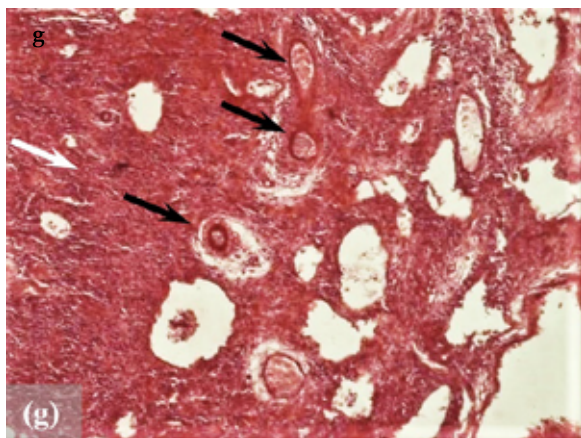
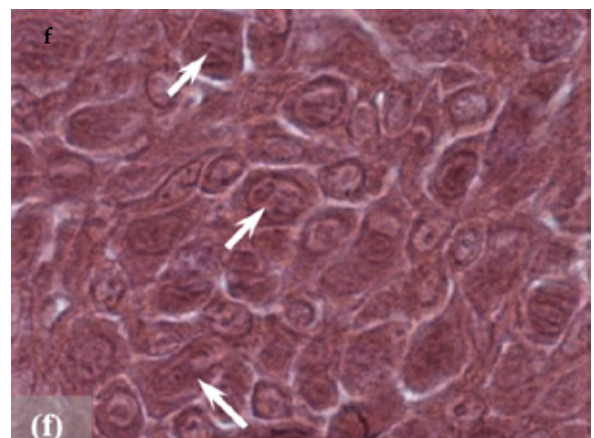
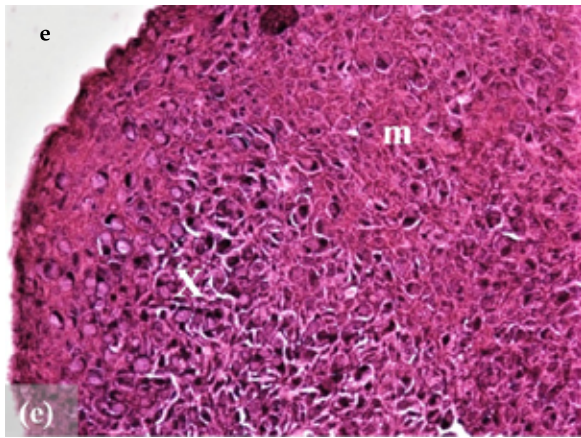
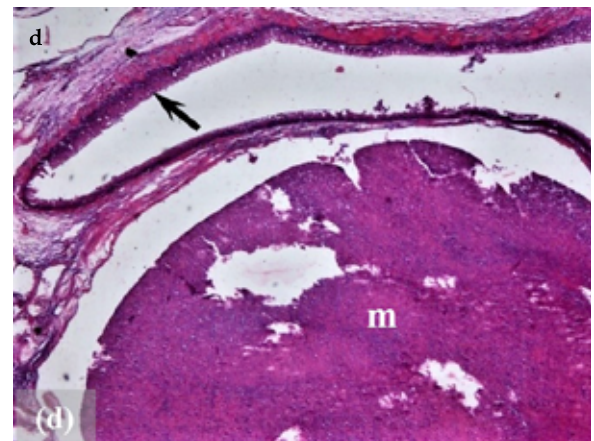
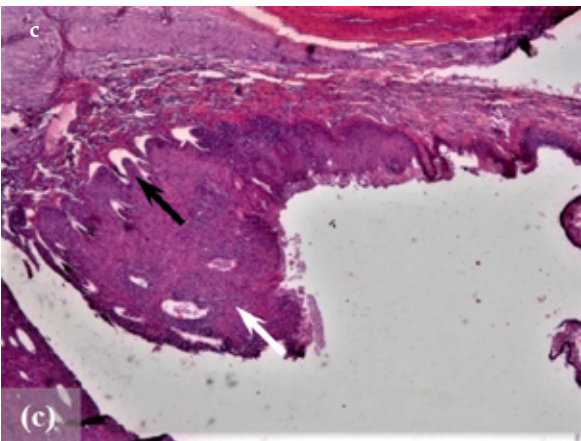
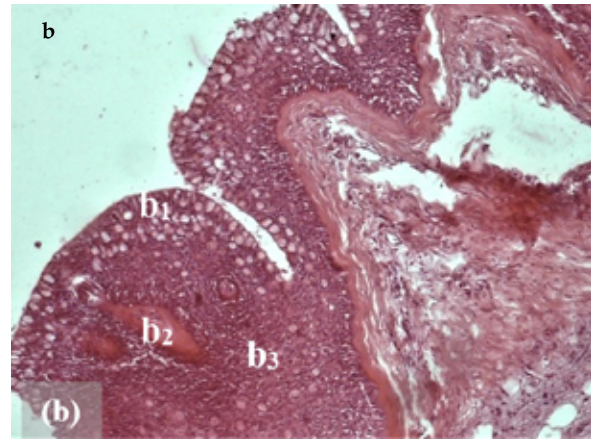
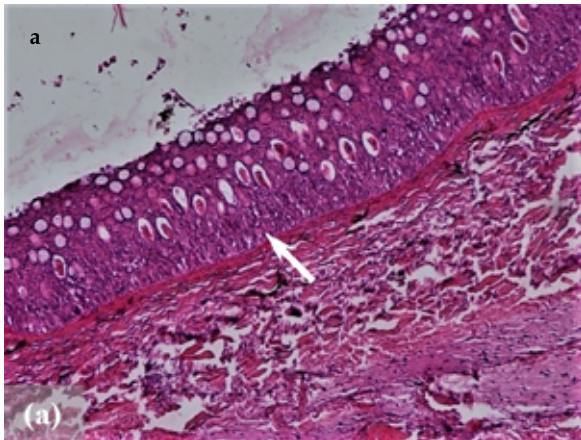
No abnormal lesions were observed in other areas of the skin. In addition, there were no signs of metastasis diagnosed in the internal organs through the necropsy.

The median length, weight, and age of examined fish were 39.03 cm, 780 g, and 4 years, respectively. The water temperature varied between 9°C and 15°C during sampling.

Histopathological findings

In the microscopic study, in 20 of 22 cases, neoplasms were diagnosed as squamous cell papilloma and in 2 of 22 cases as squamous cell carcinoma. The normal skin of lip surroundings consists of about 15 to 25 layers of epidermal non-keratinized squamous cells with many mucosal cells, among which cuboidal Malpighian cells of different thicknesses existed below them. The basal layer consists of columnar cells as a germ cell layer, and collagenous and cartilaginous dermal tissue are integrated under the epidermal layer (Figure 2a). Meanwhile, the number of epidermal cell layers was higher in the lip skin tissue, up to 50. It also contains a chemoreceptor that is scattered throughout this layer.

All investigated skin papillomas were benign neoplasms without aggressive characteristics in which the upper layer of epidermal cells was reduced or destroyed, and undifferentiated cubic Malpighian cells without aggressive characteristics were observed below it. They were smaller in size, proliferated and compacted next to



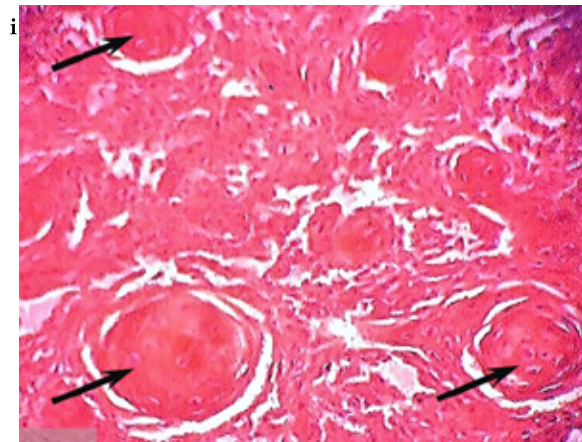


Figure 2. The histopathological study of examined tissues from *R. kutum*

a) Section of normal tissue containing 15 to 30 layers of different cells (arrow), plenty of mucosal cells and the normal basal membrane (H&E staining, x100 magnification); b) Section of lip skin tissue, the normal epithelium (b_1), chemoreceptors (b_2), and hyperplastic layer of squamous cells (b_3) (H&E staining, x40 magnification); c) The hyperplastic epidermal tissue (white arrow) (H&E staining, x100 magnification); d) A hyperplastic mass of undifferentiated and non-specialized Malpighian cells (m) and reduction of mucous cells compared to normal epithelial tissue (arrow) (H&E staining, x40 magnification); e) Papillomatosis with X-cells (X), tumor cells of Malpighian character with normal shape (m) (H&E staining, x 400 magnification); f) Tumor cells in mitotic stage (arrows) (H&E staining, x1000 magnification); g) Connective tissue with tumor cells (white arrow) and developed vessels (vascularization) at the base and center of the tumor (black arrows) (H&E staining, x100 magnification); h) Pleomorphic squamous epithelial cells arising from the epidermis and extending into the dermis (black arrows) (H&E staining, x100 magnification); and i) Squamous cell carcinoma; keratin pearls, central keratinization surrounded by concentric layers of abnormal squamous cells (black arrows) (H&E staining, x100 magnification).

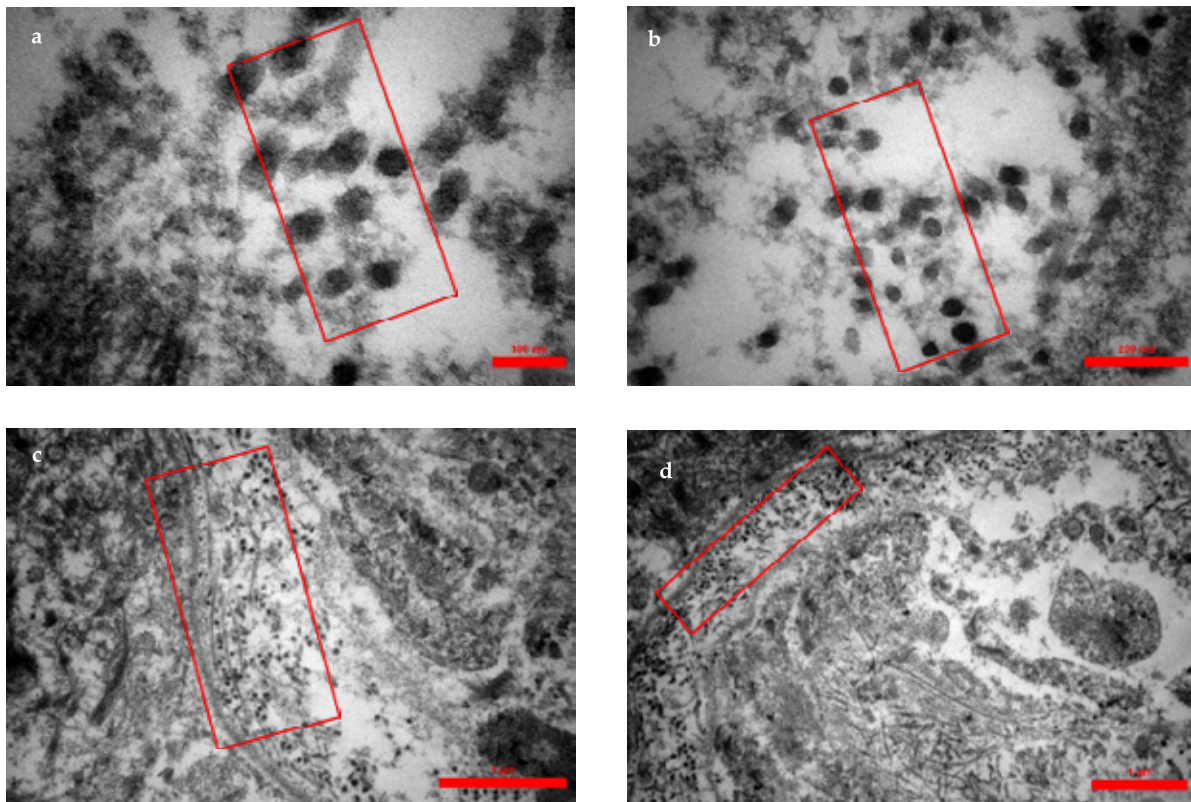


Figure 3. Electron micrograph of the cytoplasm and nuclei of x-cells

Virus-like particles are dense in both cytoplasm (a, b, c) and nucleus (d), The aggregations of these particles are labeled with a red rectangle, presented in various magnifications (scale bar a:100 nm, b: 200 nm, c: 1 μ m, d: 1 μ m)

each other. This Malpighian layer was much thicker than normal lip tissue, and the mitotic stage was observable in the cells. Furthermore, mucosal cells were completely destroyed. In addition, the chemoreceptors had disappeared or were compressed by the surrounding hyperplastic tissue. Large and rounded Malpighian cells called X cells were present in some cases. Vascular tissue was also developed in the base and central part of the tumors, which are responsible for blood supply and nutrition to the abundant and dividing cells of the tumor tissue (Figure 2c-g).

In the samples with squamous cell carcinoma (a malignant tumor of squamous cells), besides the significant increase in undifferentiated Malpighian cells, mucosal cells were reduced or disappeared, and the tumor cells were single or clusters of several interconnected and polymorphic epidermal cells. Under the basal layer and inside the dermis tissue, nests of Malpighian cells with a keratin center (horn pearl) were observed, a notable symptom of squamous cell carcinoma. Complete necrosis of the dermis was observed in some places. Tumorous cells are large and oval; their cytoplasm is slightly basophilic and has a large centric nucleus. Vascular development was seen around the tumor, and no mitotic forms were observed (Figure 2h and 2i).

Transmission electron microscopy

Transmission electron microscopy results also revealed the existence of virus-like particles in tumor lesions. The virus-like particle aggregation was observable within the cytoplasm and nuclei in some cells (Figure 3).

Discussion

As far as we know, this is the first report of proliferative skin lesions detected in Caspian white fish with suspected oncogenic viral etiology. The tumor manifestation in fish of the Caspian Sea was previously reported in its northern territories (Romanov & Altufiev, 1990; Volodina et al., 2016; Zhimbej & Mitrofanov, 2002). However, considering the frequent reports of heavy metal concentration in fish species of the southern Caspian Sea (Sheikhzadeh & Hamidian, 2021; Shohreh et al., 2020), there is no available report of tumor incidence in the fish population of this region.

According to the comparative histopathological studies, there are no remarkable differences between tumors in fish and comparable mammalian tumors; therefore, fish tumors are classified on much the same basis as mammal tumors (Masahito et al., 1988). In addition, tumor sup-

pression mechanisms in fish, as an evolutionarily older and genetically diverse group, revealed novel mechanisms along with known tumor suppression mechanisms in mammals (Baines et al., 2022). Likewise, tumors of skin tissue are the most prevalent types of tumors in fish and humans (Linares et al., 2015).

The most common skin tumors are papillomas, which mostly have a wart-like or flat appearance. These benign lesions are prominent parts of the epidermis with the proliferation of Malpighian cells with reduced and removed goblet and rod cells by displacement or necrosis (Ferguson, 1989; Mokhtar, 2017).

This type of neoplasia was also recently reported, such as in *Salvelinus leucomaenis* and *Carassius auratus*, with proliferation in epithelial cells, also observed in sections of *R. kutum*. However, contrary to the etiology of papilloma in the mentioned cases, it was detected as non-viral (Lanteri et al., 2016; Sergeenko et al., 2021). In 2014, an epidermal papilloma was reported in *Pterygoplichthys joselimaianus* with extensive hyperplasia of Malpighian cells that confirms our findings (Rahmati-Holasoo et al., 2014). Peters and Watermann (1979) reported three types of skin papillomas in flat fish with X cells with large nucleus and nucleolus and abundant vacuoles inside the cytoplasm. This finding confirms the current research results.

Squamous cell carcinoma (SCC) develops from squamous cells in the upper part of the epidermis layer. Circular nest is the most distinguished characteristic of this type of neoplasia that appears when several Malpighian cells gather together and form clumps; they become necrotic and layered, and chitinous secretions gather in the center (Ferguson, 1989; Mocho & Pereira, 2022). In SCC cases of this study, keratin production and cell necrosis had started in the center of some circular nests and were also completed in others.

Although squamous cell carcinoma is less prevalent than squamous cell papilloma, it had been recently reported in *Scardinius erythrophthalmus* and *Astronotus ocellatus* in which epithelial keratinous pearls were seen similar to carcinoma of *R. kutum*, even though in some cases of *S. erythrophthalmus* metastases had been observed in the viscera, no signs of metastasis was observed in *R. kutum* cases (Hanjavanit & Mulcahy, 2004; Rahmati-holasoo et al., 2010).

Among all studies on fish oncology and various etiologies of tumor incidences, the virus-associated tumors have been studied most extensively, especially those that

appeared in the skin, regarding their visibility (Anders & Yoshimizu, 1994; Orioles et al., 2021; Vergneau-Grosset et al., 2017). However, detrimental but not oncogenic Betanodavirus has previously been isolated and identified in fish species of the southern Caspian Sea (Shohreh et al., 2020; Soltani et al., 2010). Based on previous studies, the various types of DNA and RNA viruses had been diagnosed as the cause of these tumorigenesis in piscine species (Kibenge, 2016). Unfortunately, due to exceptional circumstances, it was impossible to analyze the skin and tissue samples of *R. kutum* using PCR.

Conclusion

In conclusion, this is the first report of fish neoplasm detected in the southern Caspian Sea. In the present research, two types of neoplastic skin lesions were identified as squamous cell papilloma and squamous cell carcinoma in the Caspian white fish; virus-like particles were detected later in ultra-thinned neoplastic tissues.

Ethical Considerations

Compliance with ethical guidelines

There were no ethical considerations to be considered in this research.

Funding

This research did not receive any grant from funding agencies in the public, commercial, or non-profit sectors.

Authors' contributions

Conceptualization, methodology, preparation of materials and financial resources: Mohaddes Ghasemi and Somayeh Haghghi Karsidani; Formal analysis: Mohaddes Ghasemi, Issa Sharifpour and Hasti Azarabad; Writing the original draft: Zahra Eynizadeh and Mohaddes Ghasemi; Data collection, review, editing and final approval: All authors; Supervision: Mohaddes Ghasemi.

Conflict of interest

The authors declared no conflict of interest.

Acknowledgments

The authors sincerely thank Reza Nahrvar for his unconditional support during field sampling. The authors also appreciate the Department of Aquatic Health and Disease of the Inland Waters Aquaculture Research Center.

References

- Anders, K., & Yoshimizu, M. (1994). Role of viruses in the induction of skin tumours and tumour-like proliferations of fish. *Diseases of Aquatic Organisms*, 19, 215-232. [DOI:10.3354/dao019215]
- Baines, C., Meitern, R., Kreitsberg, R., & Sepp, T. (2022). Comparative study of the evolution of cancer gene duplications across fish. *Evolutionary Applications*, 15(11), 1834-1845. [DOI:10.1111/eva.13481] [PMID]
- Baumann, P. C. (1992). The use of tumors in wild populations of fish to assess ecosystem health. *Journal of Aquatic Ecosystem Health*, 1, 135-146. [Link]
- Breslauer, T. (1916). Zur kenntnis der epidermoidalgeschwulste von kaltblutern. Histologische veränderungen des integuments und der mundschleimhaut beim stint (*Osmerus eperlanus* L). *Archiv für Mikroskopie Anatomic*, 87, 200-264. [DOI:10.1007/BF02981351]
- da Rocha, C. A. M., Moreira-Nunes, C. A., da Rocha, S. M., da Silva, M. A. S., & Burbano, R. R. (2017). A review on occurrence of neoplasia in fish/Uma revisão sobre a ocorrência de neoplasias em peixes. *Acta of Fisheries and Aquatic Resources*, 5(2), 19-24. [Link]
- Farrell, J. A., Yetsko, K., Whitmore, L., Whilde, J., Eastman, C. B., & Ramia, D. R., et al. (2021). Environmental DNA monitoring of oncogenic viral shedding and genomic profiling of sea turtle fibropapillomatosis reveals unusual viral dynamics. *Communications Biology*, 4(1), 565. [DOI:10.1038/s42003-021-02085-2] [PMID]
- Fazli, H., & Parafkandeh Haghghi, F. (2016). [Spatiotemporal abundance and diversity of bonyfishes in beach seines in Iranian waters of the Caspian Sea (Persian)]. *Fisheries Science and Technology*, 5(3), 109-120. [Link]
- Ferguson, H. W. (1989). *Systemic pathology of fish. A text and atlas of comparative tissue responses in diseases of teleosts*. Iowa: Iowa State University Press. [Link]
- Goyal, S. M., & Nelson, M. D. (1984). Viral pollution of the marine environment. *Critical Reviews in Environmental Control*, 14(1), 1-32. [DOI:10.1080/10643388409381712]
- Groff, J. M. (2004). Neoplasia in fishes. *The Veterinary Clinics of North America. Exotic Animal Practice*, 7(3), 705-vii. [DOI:10.1016/j.cvex.2004.04.012] [PMID]
- Hanjavanit, C., & Mulcahy, M. F. (2004). Squamous cell carcinoma in rudd *Scardinius erythrophthalmus*: Histopathology, ultrastructure, and transmission. *Diseases of Aquatic Organisms*, 61(3), 215-226. [DOI:10.3354/dao061215] [PMID]
- Harshbarger, J. C., & Clark, J. B. (1990). Epizootiology of neoplasms in bony fish of North America. *The Science of the Total Environment*, 94(1-2), 1-32. [DOI:10.1016/0048-9697(90)90362-x] [PMID]
- Harshbarger, J. C., Spero, P. M., & Wolcott, N. M. (2021). Neoplasms in wild fish from the marine ecosystem emphasizing environmental interactions. In: J. A. Couch, & J. W. Fournie (Eds.), *Pathobiology of marine and estuarine organisms* (pp. 157-176). Boca Raton: CRC Press. [DOI:10.1201/9781003069058-6]
- Kibenge, F. S., & Godoy, M. G. (2016). *Aquaculture virology*. Massachusetts: Academic Press. [Link]

- Lanteri, G., Ieni, A., Toffan, A., Abbate, J., Saraò, M., & Barresi, V., et al. (2016). Immunohistochemical patterns of a non-viral papilloma in Goldfish (*Carassius auratus*, L.). *Bulletin of The European Association of Fish Pathologists*, 36(5), 208-213. [Link]
- Linares, M. A., Zakaria, A., & Nizran, P. (2015). Skin cancer. *Primary Care*, 42(4), 645-659. [DOI:10.1016/j.pop.2015.07.006] [PMID]
- Masahito, P., Ishikawa, T., & Sugano, H. (1988). Fish tumors and their importance in cancer research. *Japanese Journal of Cancer Research: Gann*, 79(5), 545-555. [DOI:10.1111/j.1349-7006.1988.tb00021.x] [PMID]
- Mirzajani, A., Hamidian, A. H., Abbasi, K., & Karami, M. (2016). Distribution and abundance of fish in the southwest of Caspian Sea coastal waters. *Russian Journal of Marine Biology*, 42(2), 178-189. [DOI:10.1134/S1063074016020073]
- Mocho, J. P., & Pereira, N. (2022). Health monitoring, disease, and clinical pathology. In: L. D'Angelo, & P. de Girolamo (Eds.), *Laboratory fish in biomedical research* (pp. 81-100). Massachusetts: Academic Press. [DOI:10.1016/B978-0-12-821099-4.00014-6]
- Mokhtar, D. M. (2017). *Fish histology: from cells to organs*. New York: Apple Academic Press. [DOI:10.1201/9781315205779]
- Orioles, M., Galeotti, M., Patarnello, P., Pizzolitto, S., & Volpatti, D. (2021). Histological and ultrastructural description of benign adipocytic tumors in farmed striped Sea Bream (*Lithognathus mormyrus*). *Animals*, 11(12), 3413. [DOI:10.3390/ani1123413] [PMID]
- Peters, N., & Watermann, B. (1979). Three types of skin papillomas of flatfishes and their causes. *Marine Ecology Progress Series*, 1, 269-276. [DOI:10.3354/meps001269]
- Rahmati-Holasoo, H., Hobbenaghi, R., Tukmechi, A., & Morvaridi, A. (2010). The case report on squamous cell carcinoma in Oscar (*Astronotus ocellatus*). *Comparative Clinical Pathology*, 19(4), 421-424. [DOI:10.1007/s00580-010-0963-z]
- Rahmati-Holasoo, H., Shokrpour, S., Mousavi, H. A., & Ahmadpoor, M. (2014). Epidermal papilloma in a gold spot plecostomus (*Pterygoplichthys joselimaianus* Weber, 1991). *Bulletin of the European Association of Fish Pathologists*, 34(4), 117-123. [Link]
- Reynolds, E.S. (1963). The use of lead citrate at a high pH as an electron opaque stain in electron microscopy. *Journal of Cell Biology*, 17, 208-212. [DOI: 10.1083/jcb.17.1.208] [PMID]
- Romanov, A. A., & Altufiev, Y. V. (1990). Tumors in gonads and liver of the Caspian Sea sturgeons (*Acipenseridae*). *Voprosy Ikhtiologii*, 30, 1040-1044. [Link]
- Samavat, Z., Shamsaie Mehrgan, M., Jamali, S., Soltani, M., & Hosseini Shekarabi, S. P. (2019). Determination of grapefruit (*Citrus paradisi*) peel extract bio-active substances and its application in Caspian white fish (*Rutilus frisii kutum*) diet: Growth, haemato-biochemical parameters and intestinal morphology. *Aquaculture Research*, 50(9), 2496-2504. [DOI:10.1111/are.14204]
- Sergeenko, N. V., Gavrusheva, T. V., Ustimenko, E. A., Bochkova, E. V., & Ryazanova, T. V. (2021). Case of highly prevalent papilloma-like skin lesions in whitespotted char (*Salvelinus leucomaenis*) in Kamchatka (Russia). *Journal of Fish Diseases*, 44(5), 487-493. [DOI:10.1111/jfd.13328] [PMID]
- Sheikhzadeh, H., & Hamidian, A. H. (2021). Bioaccumulation of heavy metals in fish species of Iran: A review. *Environmental Geochemistry and Health*, 43(10), 3749-3869. [DOI:10.1007/s10653-021-00883-5] [PMID]
- Shohreh, P., Azizkhani, M., & Mousavi, S. (2020). Evaluation of cadmium, lead and mercury contents in some commercially valuable fish species of Caspian Sea and Persian Gulf. *Iranian Journal of Veterinary Medicine*, 14(4), 433-441. [Link]
- Soltani, M., Ghasemi, M., Sharif, R. M., Sharifpour, E., & Zorieh, S. (2010). Isolation and identification of betanodavirus causing mass mortalities in golden grey mullet (*Liza auratus*) in the Caspian Sea. *Iranian Journal of Veterinary Medicine*, 4(3), 201-208. [DOI:10.22059/IJVM.2010.21354]
- Vergneau-Grosset, C., Nadeau, M.-E., & Groff, J. M. (2017). Fish oncology: Diseases, diagnostics, and therapeutics. *The Veterinary Clinics of North America. Exotic Animal Practice*, 20(1), 21-56. [DOI:10.1016/j.cvex.2016.07.002] [PMID]
- Volodina, V. V., Proskurina, V. V., Solokhina, T. A., Voronina, E. A., & Konkova, A. V. (2016). [Fishes from the Volga-Caspian basin - vectors of pathogens of anthroozoonoses (Russian)]. *Gigiena i sanitarii*, 95(6), 517-520. [PMID]
- Zhimbey, Y. N., & Mitrofanov, I. V. (2001). *Histopathologies in fish from north Caspian Sea*. Paper presented at: poster session of 10th European Congress of Ichthyology (ECI X), Prague, September 3-7, 2001. [Link]

مطالعه پژوهشی

ضایعات توموری در ماهی سفید دریای خزر (*Rutilus kutum*)*محدث قاسمی^۱، عیسی شریف‌پور^۲، سمیه حقیقی کارسیدانی^۳، زهرا عینی زاده^۴، هستی آذرآباد^۵

۱. پژوهشکده آبی‌پروری آب‌های داخلی کشور، مؤسسه تحقیقات علوم شیلاتی کشور، سازمان تحقیقات، آموزش و ترویج کشاورزی، بندرانزلی، ایران.
۲. مؤسسه تحقیقات علوم شیلاتی کشور، سازمان تحقیقات، آموزش و ترویج کشاورزی، تهران، ایران.
۳. گروه شیلات، دانشکده منابع طبیعی، واحد بندرانزلی، دانشگاه آزاد اسلامی، بندرانزلی، ایران.
۴. گروه علوم جانوری، دریا و آبیان، دانشکده علوم و فناوری زیستی، دانشگاه شهید بهشتی، تهران، ایران.
۵. گروه باتولوژی، بیمارستان دامپزشکی حمیدرضا فتاحیان، تهران، ایران.

Use your device to scan and read the article online



How to Cite This Article Ghasemi, M., Sharifpour, I., Haghighi Karsidani, S., Eynizadeh, Z., & Azarabad, H. (2024). Tumor Lesions in the Caspian White Fish (*Rutilus kutum*). *Iranian Journal of Veterinary Medicine*, 18(2), 291-300. <http://dx.doi.org/10.32598/ijvm.18.2.1005373>

doi <http://dx.doi.org/10.32598/ijvm.18.2.1005373>

چکیده



زمینه مطالعه: امروزه بروز ضایعات توموری در گونه‌های مختلف مهره‌داران به دلیل سبب‌شناسی چند عاملی به یک موضوع بحرانی تبدیل شده است. این امر لزوم توجه بیشتر به گونه‌های موجود در اکوسیستم‌های آبی را به‌عنوان زیستگاه محصور دو چندان می‌کند. به‌علاوه، آگاهی از دلایل ایجاد تومور در صنعت آبی‌پروری باعث افزایش کیفیت محصولات و افزایش سود خواهد شد.

هدف: این مطالعه برای اولین بار به معرفی ضایعات توموری و خصوصیات و علل احتمالی آن در ماهی سفید دریای خزر (*Rutilus kutum*) به‌عنوان مهم‌ترین ماهی استخوانی اقتصادی در جنوب دریای خزر می‌پردازد.

روش کار: بدین منظور، پس از بررسی‌های بالینی ماهیان مشکوک، مطالعات آسیب‌شناسی بافتی و سنجش‌های میکروسکوپ الکترونی بر روی بیش از ۲۰ نمونه انجام شد.

نتایج: نتایج بررسی‌ها بروز کارسینوم و پاپیلوم سلول‌های سنگفرشی را در مقاطع بافتی مورد مطالعه نشان داد. علاوه‌براین، ذرات شبه ویروسی به وضوح در میکروگراف‌های تهیه‌شده از بافت توموری مشاهده شد که نشان‌دهنده علت احتمالی ویروسی ضایعات توموری در ماهی سفید دریای خزر می‌باشد.

نتیجه‌گیری نهایی: این مطالعه اولین گزارش بروز تومور در گونه‌های ماهی جنوب دریای خزر می‌باشد که می‌تواند هشدار برای سلامت اکوسیستم مذکور و کل صنعت آبی‌پروری باشد.

کلیدواژه‌ها: دریای خزر، تومور ماهی، کارسینوم سلول‌های سنگفرشی، پاپیلوم سلول‌های سنگفرشی، ویروس‌های تومورزا

تاریخ دریافت: ۲۵ مرداد ۱۴۰۲

تاریخ پذیرش: ۱۷ آبان ۱۴۰۲

تاریخ انتشار: ۱۳ فروردین ۱۴۰۳

* نویسنده مسئول:

دکتر محدث قاسمی

نشانی: بندرانزلی، سازمان تحقیقات، آموزش و ترویج کشاورزی، پژوهشکده آبی‌پروری آب‌های داخلی کشور.

تلفن: ۴۴۴۲۴۰۵۵ (۱۳) ۰۹۸

رایانامه: mohades@yahoo.com

This Page Intentionally Left Blank